



AcceleDent® Case Report

Straty Righellis, DDS

Oakland, CA



Summary

 Female

 49 years of age

 Projected Treatment Time: 18 months






 Actual Treatment Time: 12 months 2 weeks

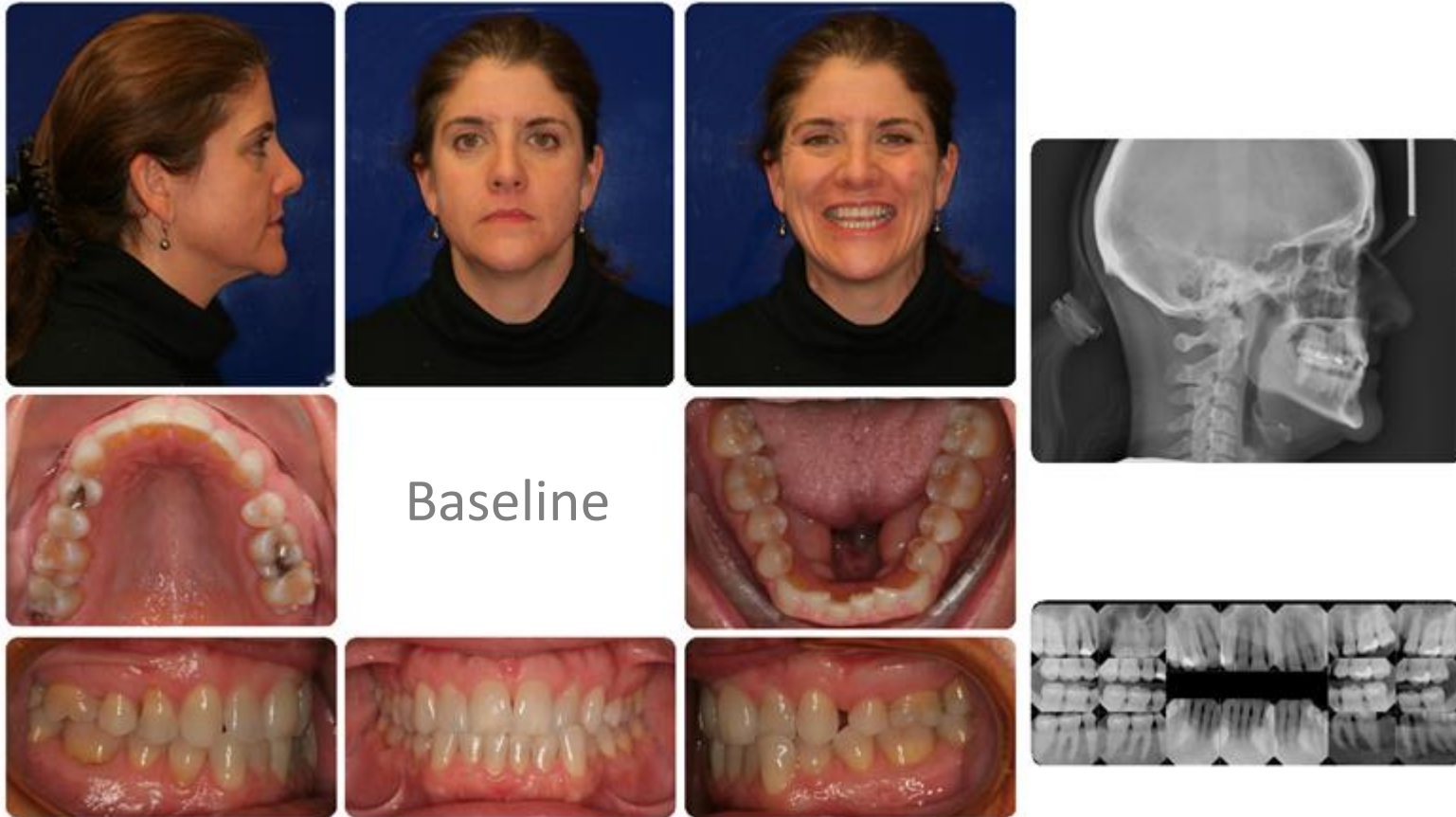 .022 Hybrid Appliance

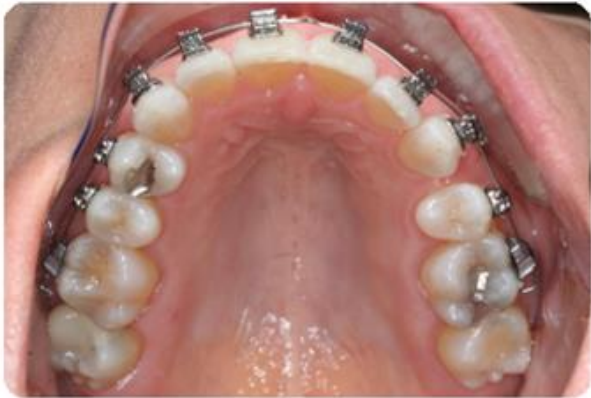 Anterior Teeth: Prodigy Active SLB

 Bicuspid Teeth: Passive SLB

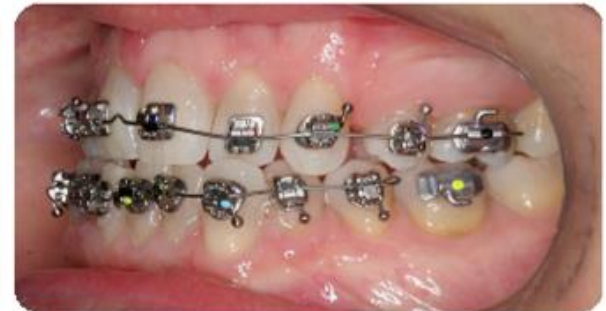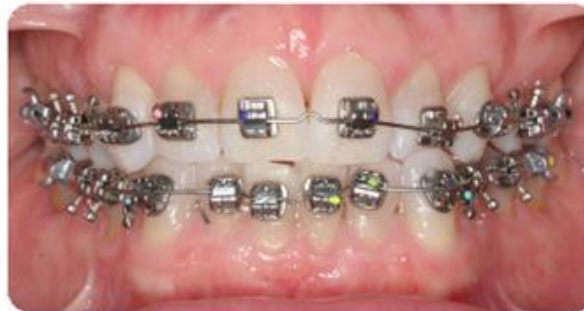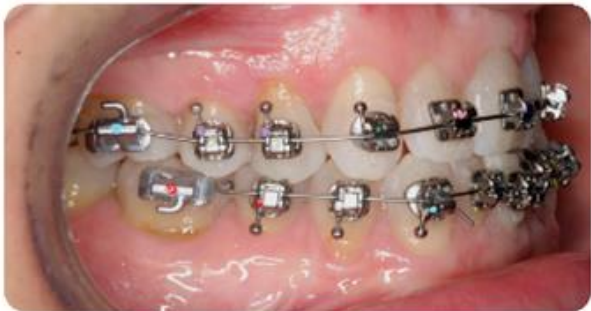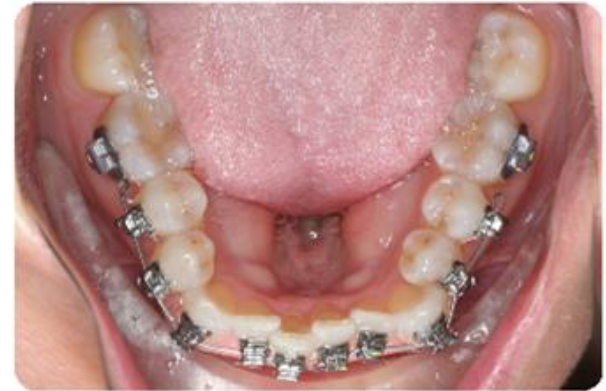Treatment Objectives

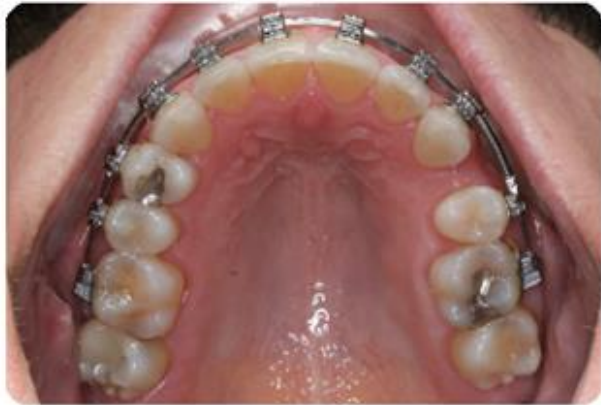-  Reestablish space in #12 area for replacement tooth
-  Establish mutually protected occlusion
-  Maintain facial profile
-  Eliminate crowding
-  Correct functional cross bite



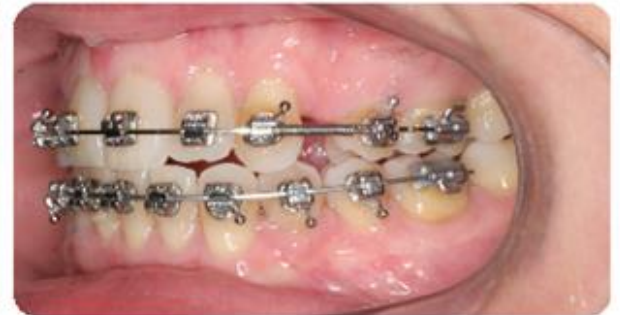
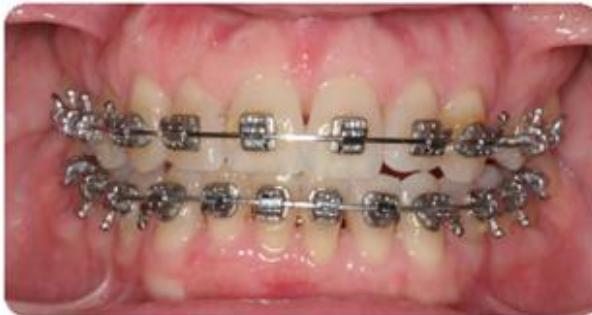
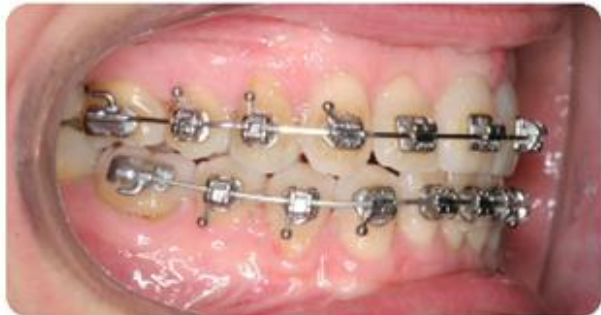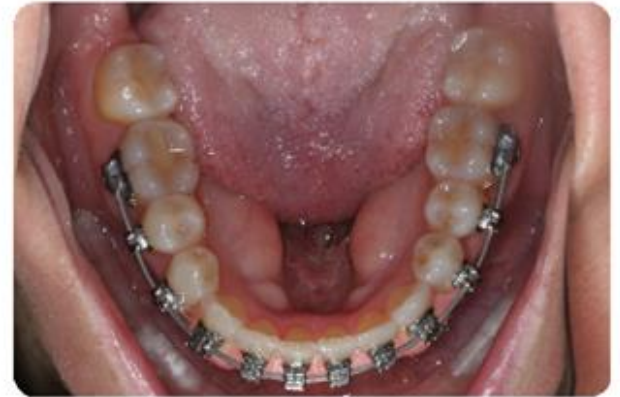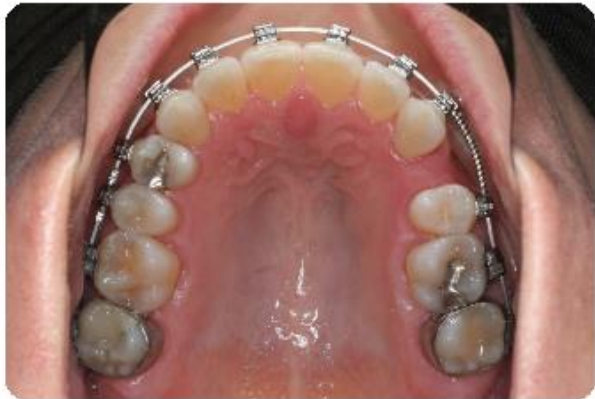4-30-2012



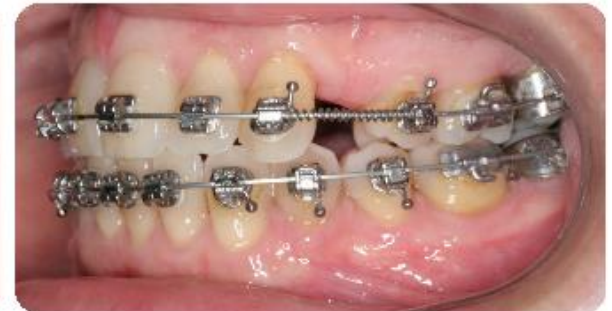
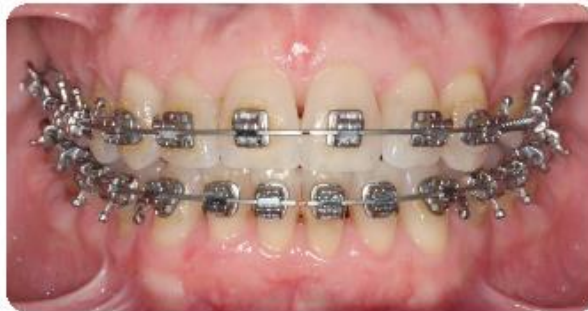
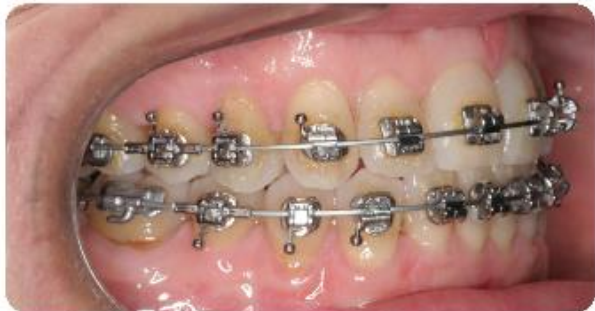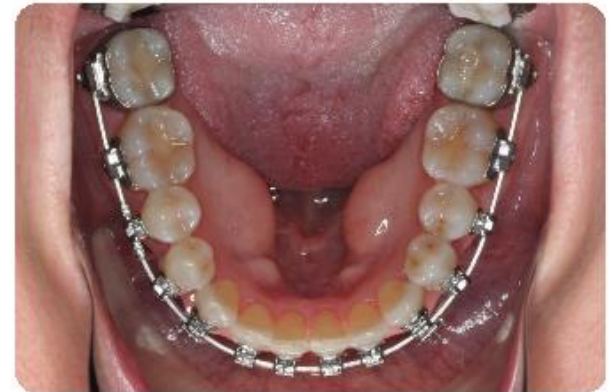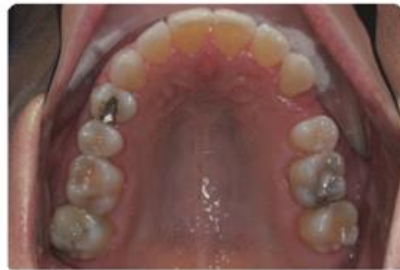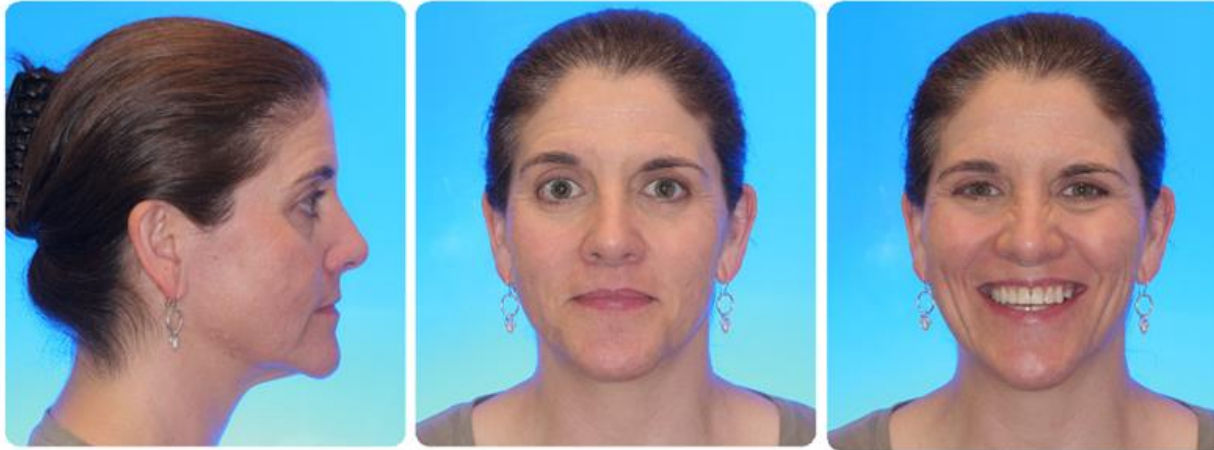10-17-2012
6 Months



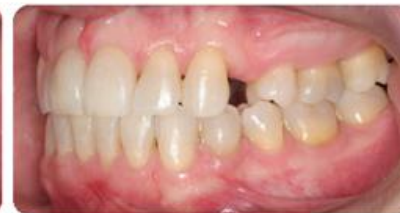
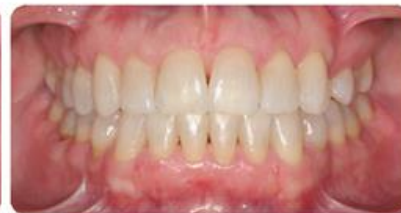
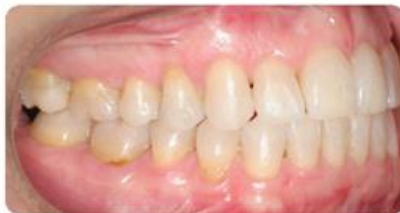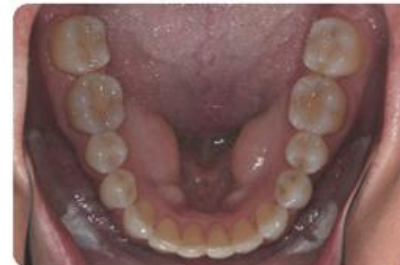1-23-2013
9 Months





5-15-2013
12 Months 2 Weeks



5-16-2013
Final Record with Pontic
12 Months 2 Weeks

