



# AcceleDent® Case Report

## Dr. Sharon Orton-Gibbs

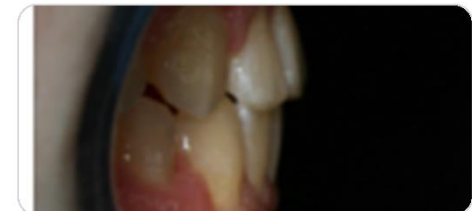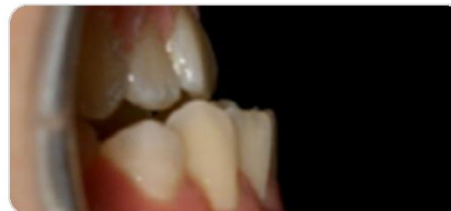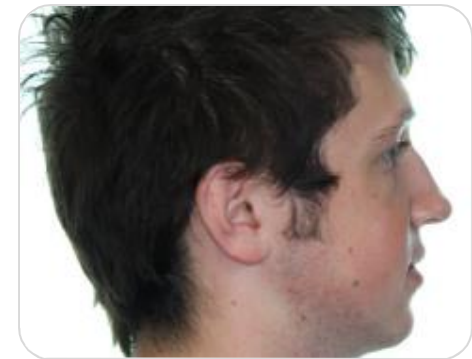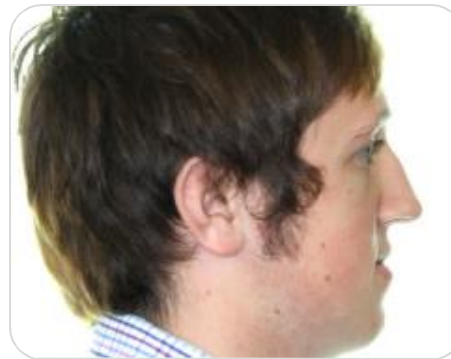Surrey, UK



# Summary

## ***18 year old male***

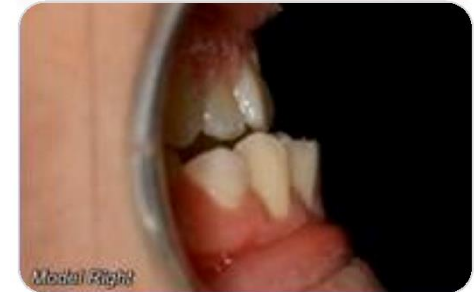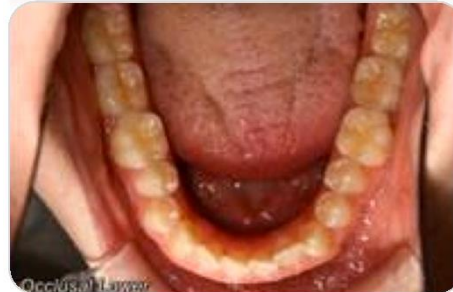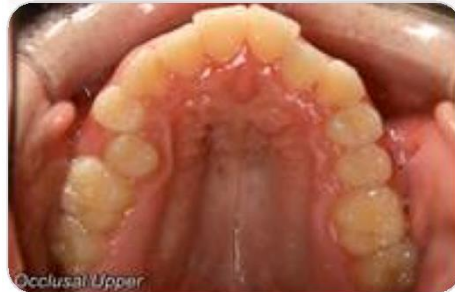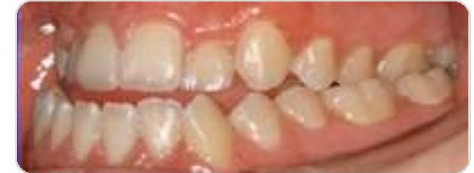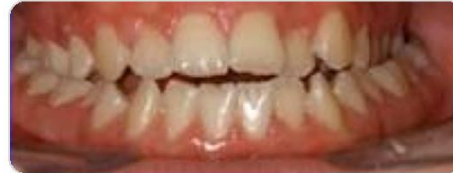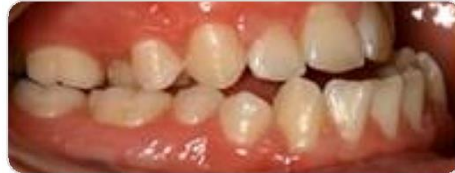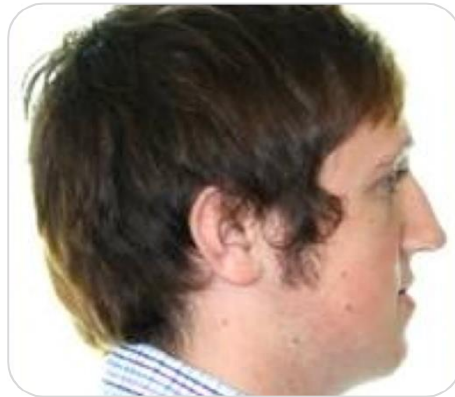- Class III combination ortho and surgical case
- Original treatment quoted at 18 to 24 months
- Patient was in his “gap” year between college and high school
- Wanted to be treated in 12 months maximum
- ***10.5 months total treatment***



Courtesy of  
Dr. Sharon Orton-Gibbs



START

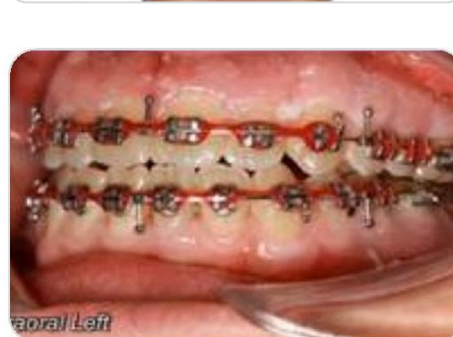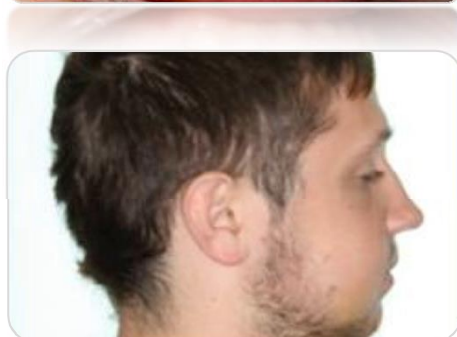

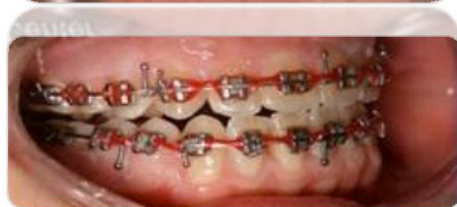
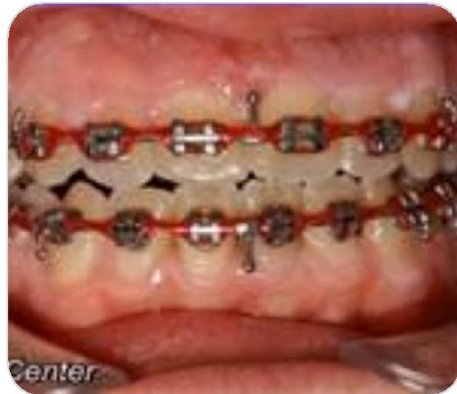
Courtesy of  
Dr. Sharon Orton-Gibbs



## INTERMEDIATE

- 5 days post-orthognathic surgery
- 9 months into treatment and 2 months of delay with travels and parents away



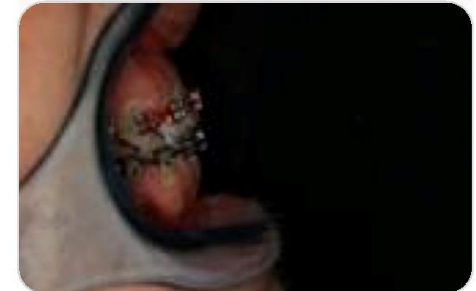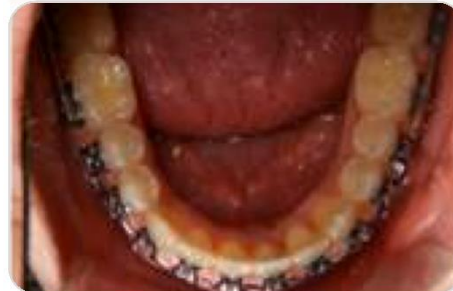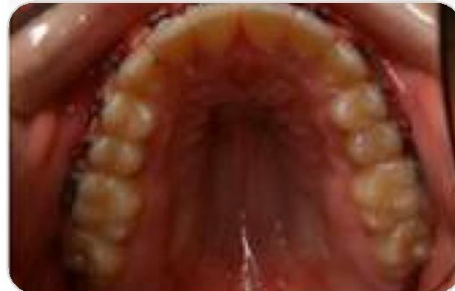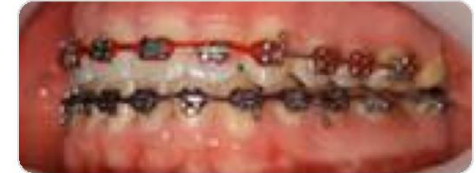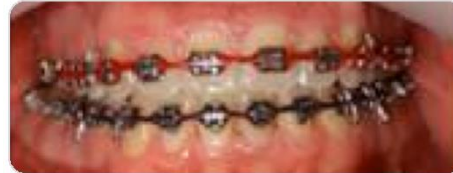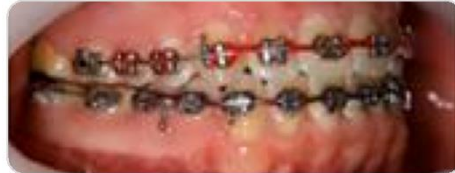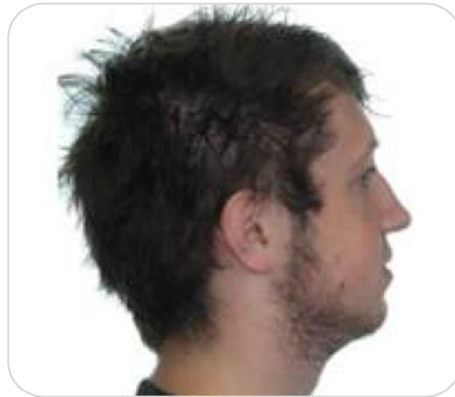Courtesy of  
Dr. Sharon Orton-Gibbs





## FINISH

- 6.5 weeks post surgery
- 46 Weeks Total Treatment Time



Courtesy of  
Dr. Sharon Orton-Gibbs





“I found using AcceleDent straightforward and uncomplicated – it was easy to include the 20 minutes routine into my day. It's great to know that I won't need to travel back from the north for more treatment and I am extremely happy with the result.”



**46 weeks total treatment**

Courtesy of  
Dr. Sharon Orton-Gibbs

