

CASE STUDY



DEMOGRAPHICS

MALE
13 YEARS OLD

DIAGNOSIS

CLASS II
CROWDING
DEEPBITE
NARROW ARCHES
END TO END BITE
POSTERIOR CROSSBITE
EXCESSIVE OVERJET

MECHANICS

DAMON® BRACKETS
FUTURE RESTORATIVE
PLANNED

TREATMENT TIME

PROJECTED TREATMENT TIME:
22 MONTHS

ACTUAL TREATMENT TIME WITH
ACCELEDENT:
13.5 MONTHS

CASE STUDY



DEMOGRAPHICS

MALE
13 YEARS OLD

DIAGNOSIS

CLASS II
CROWDING
DEEPBITE
NARROW ARCHES
POSTERIOR CROSSBITE
EXCESSIVE OVERJET

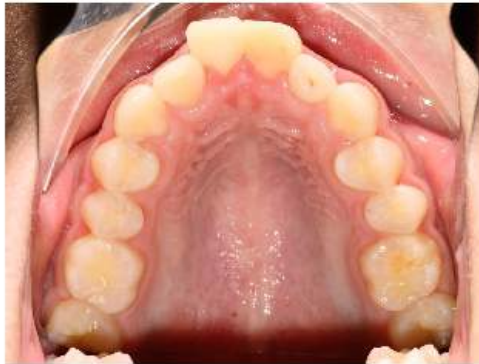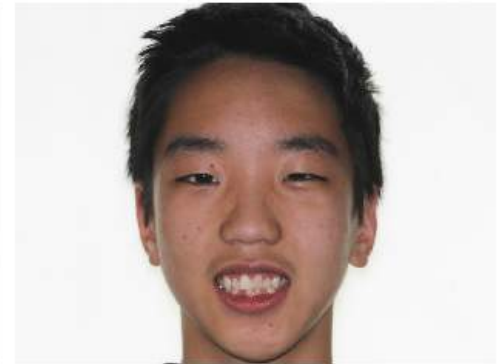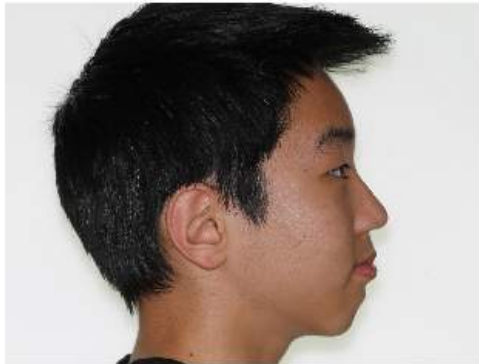MECHANICS

DAMON® BRACKETS
FUTURE RESTORATIVE
PLANNED

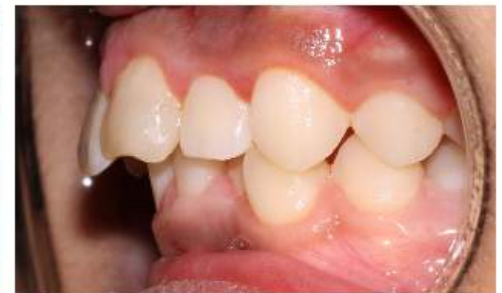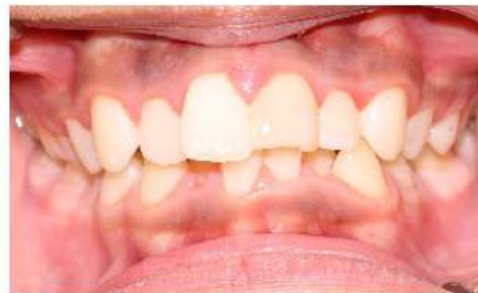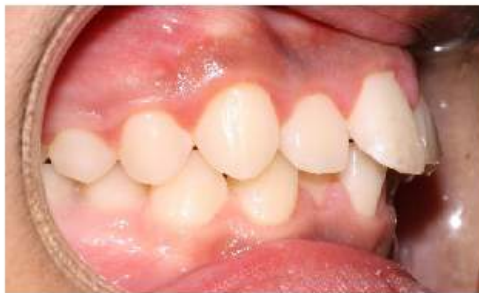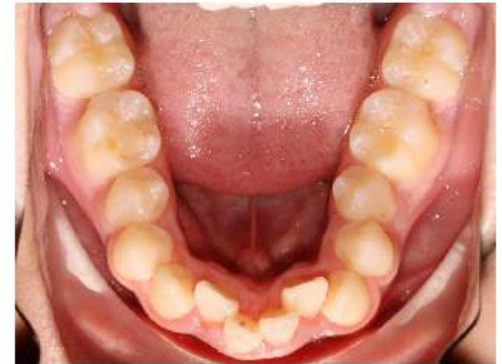TREATMENT TIME

PROJECTED TREATMENT
TIME:
22 MONTHS

ACTUAL TREATMENT
TIME WITH ACCELEDENT:
13.5 MONTHS



BASELINE



CASE STUDY



DEMOGRAPHICS

MALE
13 YEARS OLD

DIAGNOSIS

CLASS II
CROWDING
DEEPBITE
NARROW ARCHES
POSTERIOR CROSSBITE
EXCESSIVE OVERJET

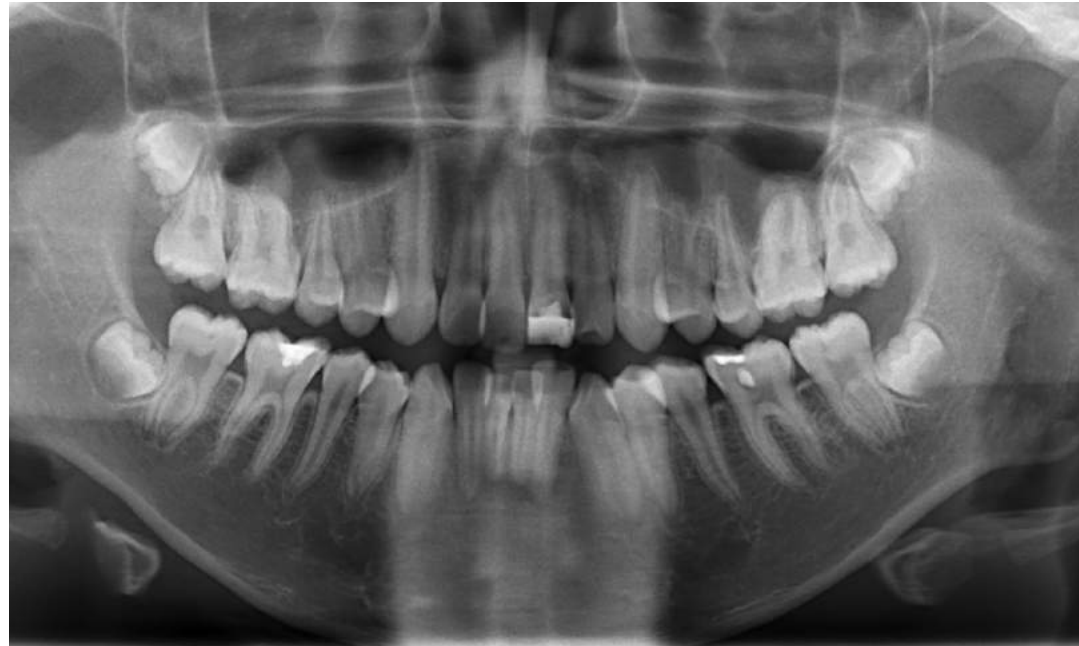
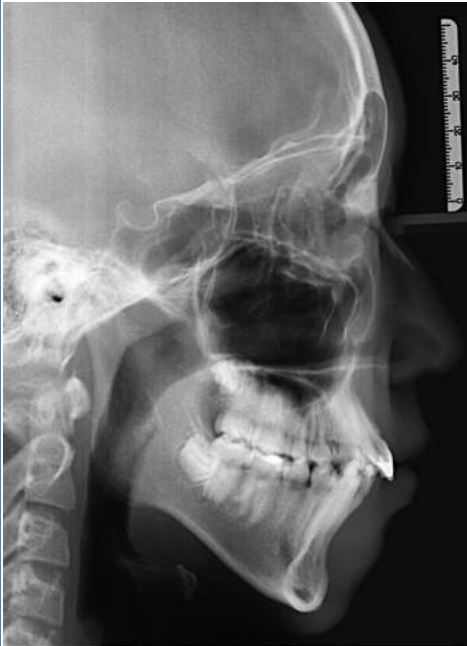MECHANICS

DAMON® BRACKETS
FUTURE RESTORATIVE
PLANNED

TREATMENT TIME

PROJECTED TREATMENT
TIME:
22 MONTHS

ACTUAL TREATMENT
TIME WITH ACCELEDENT:
13.5 MONTHS



BASELINE

CASE STUDY



DEMOGRAPHICS

MALE
13 YEARS OLD

DIAGNOSIS

CLASS II
CROWDING
DEEPBITE
NARROW ARCHES
POSTERIOR CROSSBITE
EXCESSIVE OVERJET

MECHANICS

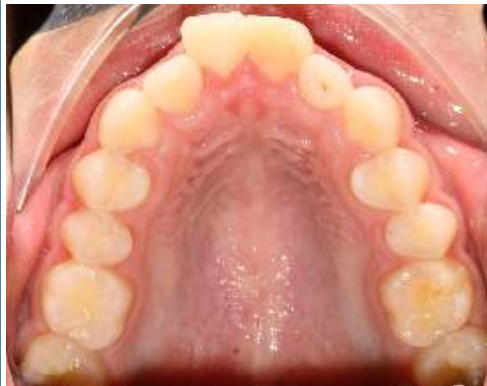DAMON® BRACKETS
FUTURE RESTORATIVE
PLANNED

TREATMENT TIME

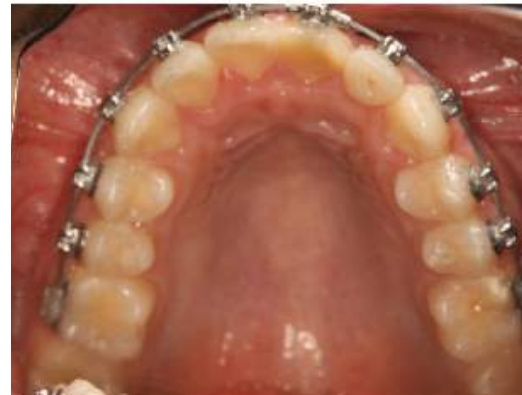PROJECTED TREATMENT
TIME:
22 MONTHS

ACTUAL TREATMENT
TIME WITH ACCELEDENT:
13.5 MONTHS

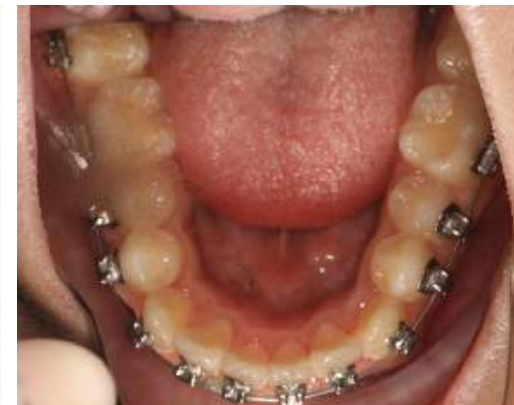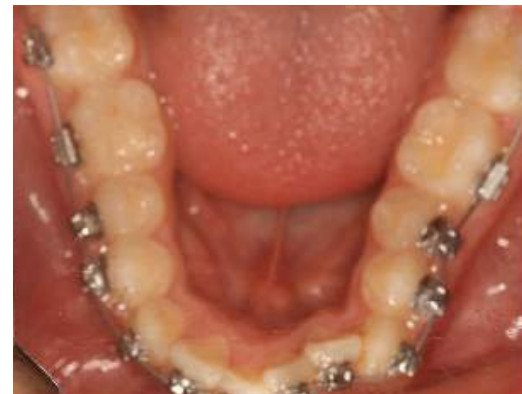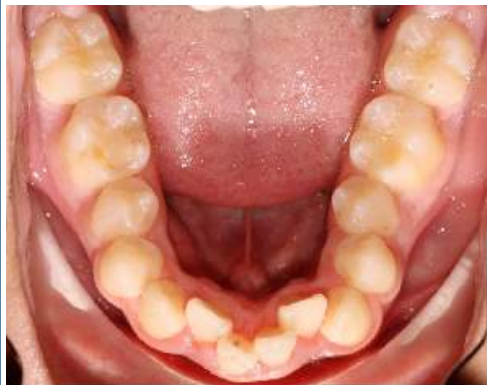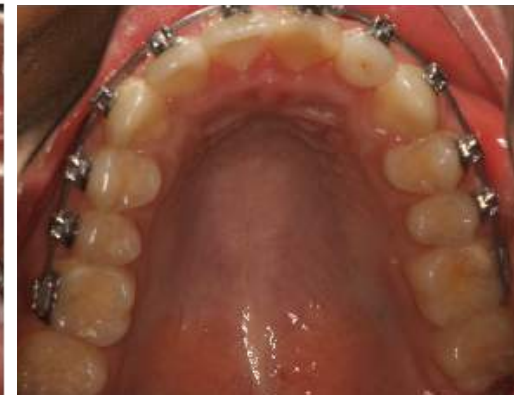BASELINE



PROGRESS: 2.5 MONTHS



PROGRESS: 4.5 MONTHS



CASE STUDY



DEMOGRAPHICS

MALE
13 YEARS OLD

DIAGNOSIS

CLASS II
CROWDING
DEEPBITE
NARROW ARCHES
POSTERIOR CROSSBITE
EXCESSIVE OVERJET

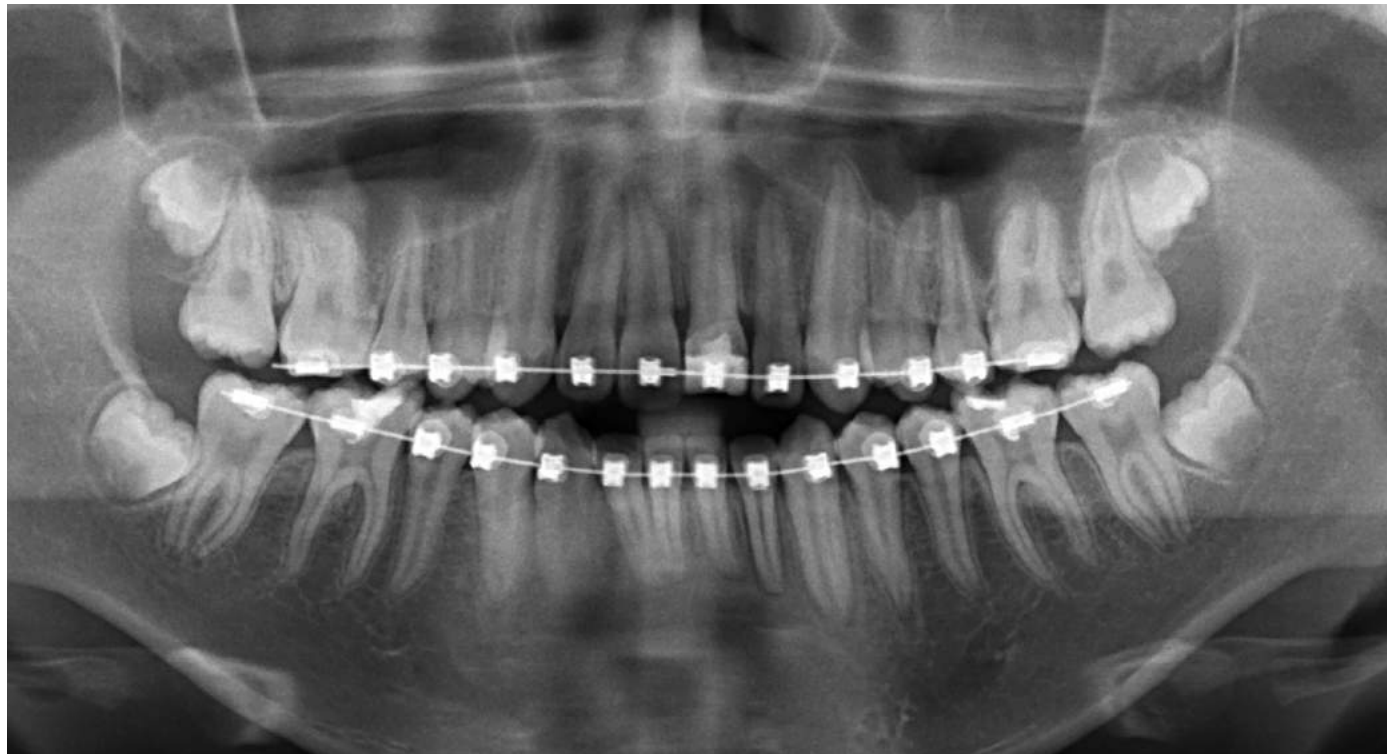
MECHANICS

DAMON® BRACKETS
FUTURE RESTORATIVE
PLANNED

TREATMENT TIME

PROJECTED TREATMENT
TIME:
22 MONTHS

ACTUAL TREATMENT
TIME WITH ACCELEDENT:
13.5 MONTHS



PROGRESS: 12 MONTHS

CASE STUDY



DEMOGRAPHICS

MALE
13 YEARS OLD

DIAGNOSIS

CLASS II
CROWDING
DEEPBITE
NARROW ARCHES
POSTERIOR CROSSBITE
EXCESSIVE OVERJET

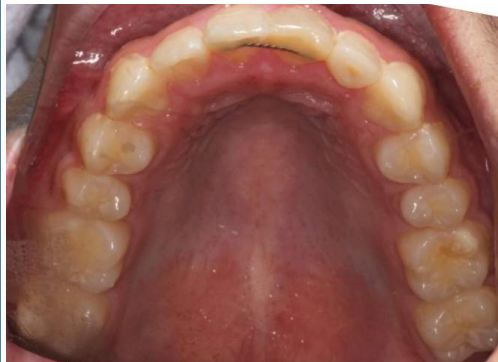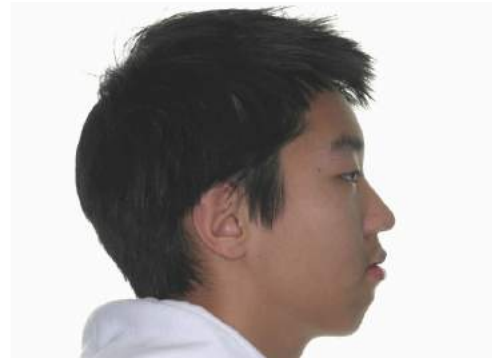MECHANICS

DAMON® BRACKETS
FUTURE RESTORATIVE
PLANNED

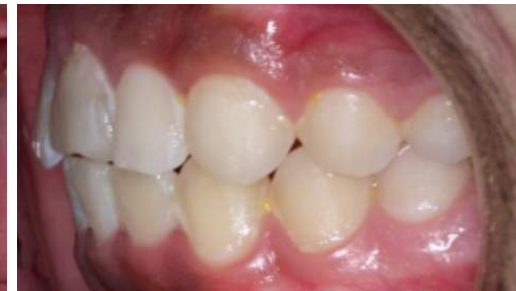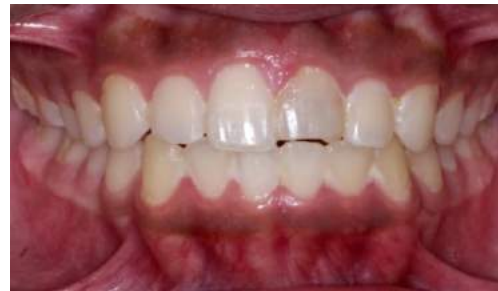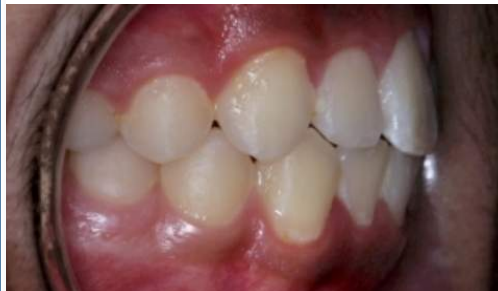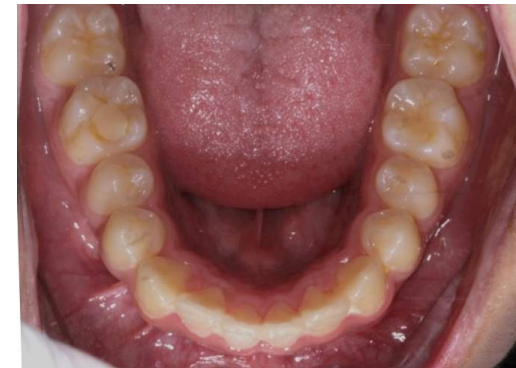TREATMENT TIME

PROJECTED TREATMENT
TIME:
22 MONTHS

ACTUAL TREATMENT
TIME WITH ACCELEDENT:
13.5 MONTHS



FINISH
Future Restorative Planned



CASE STUDY



DEMOGRAPHICS

MALE
13 YEARS OLD

DIAGNOSIS

CLASS II
CROWDING
DEEPBITE
NARROW ARCHES
POSTERIOR CROSSBITE
EXCESSIVE OVERJET

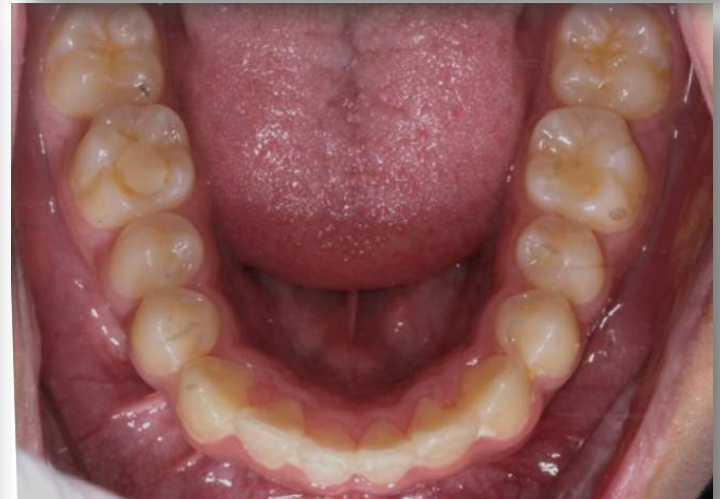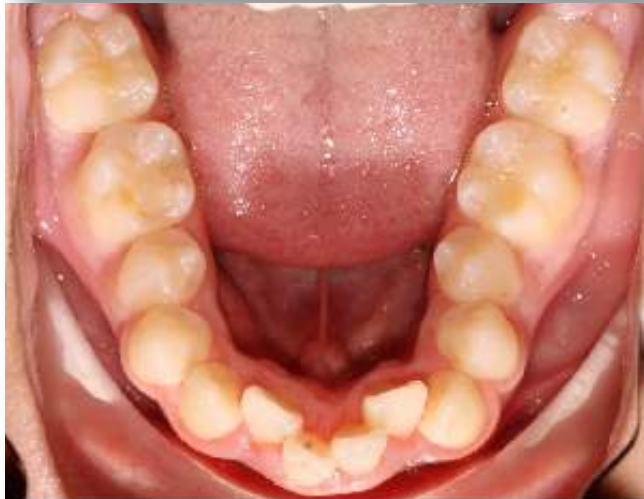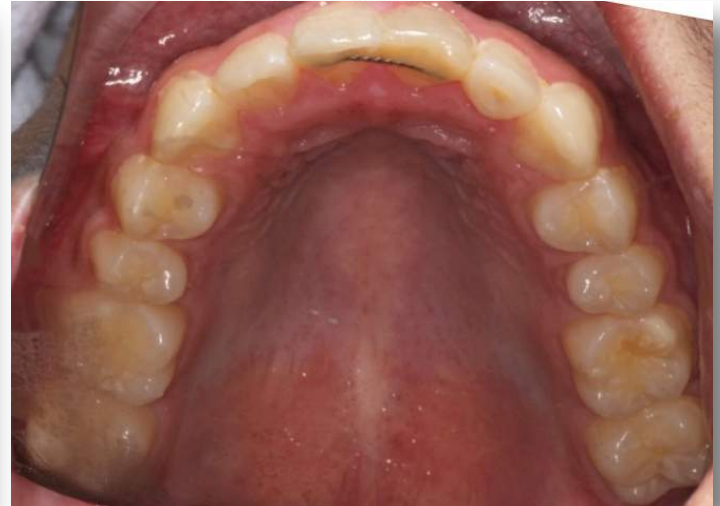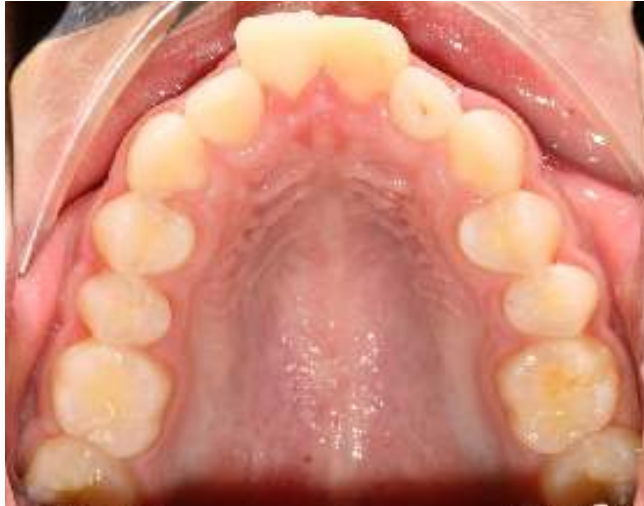MECHANICS

DAMON® BRACKETS
FUTURE RESTORATIVE
PLANNED

TREATMENT TIME

PROJECTED TREATMENT
TIME:
22 MONTHS

ACTUAL TREATMENT
TIME WITH ACCELEDENT:
13.5 MONTHS



RESULTS: 13.5 MONTHS

CASE STUDY



DEMOGRAPHICS

MALE
13 YEARS OLD

DIAGNOSIS

CLASS II
CROWDING
DEEPBITE
NARROW ARCHES
POSTERIOR CROSSBITE
EXCESSIVE OVERJET

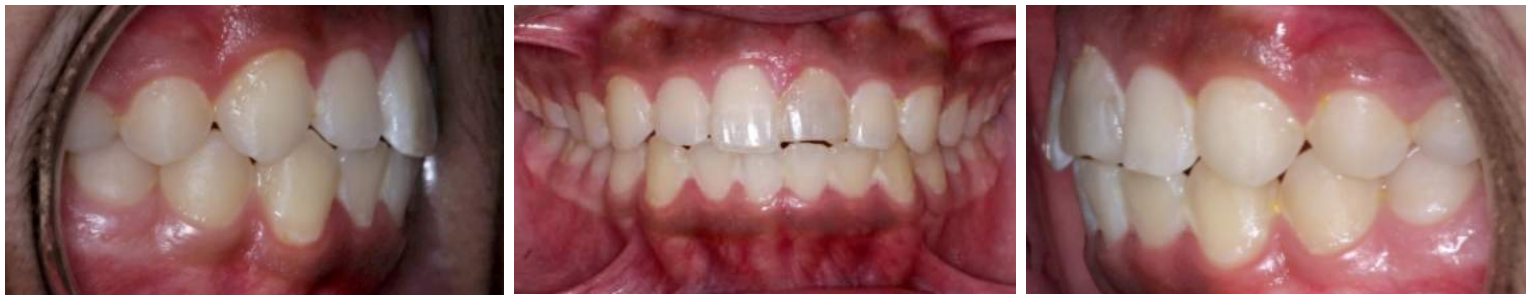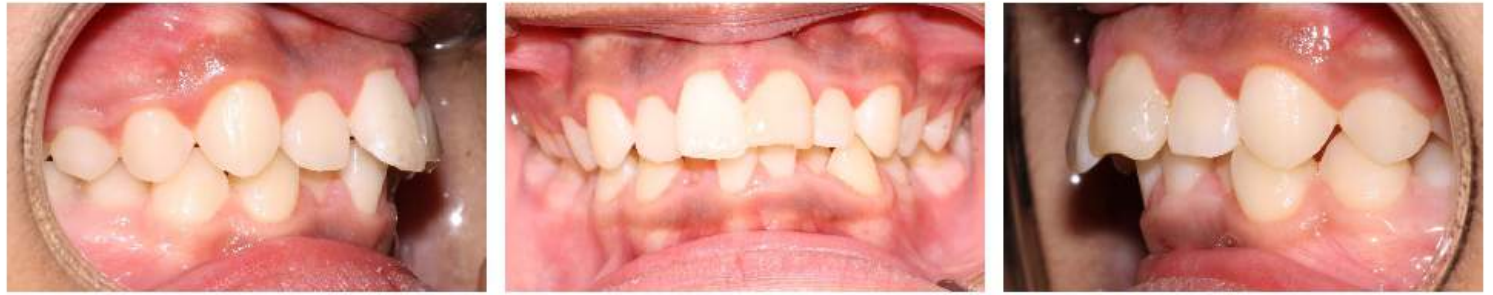MECHANICS

DAMON® BRACKETS
FUTURE RESTORATIVE
PLANNED

TREATMENT TIME

PROJECTED TREATMENT
TIME:
22 MONTHS

ACTUAL TREATMENT
TIME WITH ACCELEDENT:
13.5 MONTHS



RESULTS: 13.5 MONTHS