

CASE STUDY



DEMOGRAPHICS

FEMALE
27 YEARS OLD

DIAGNOSIS

CLASS I
MODERATE CROWDING
NARROW ARCHES
GINGIVALLY DISPLACED
MAXILLARY CANINE
MIDLINE DISCREPANCY

MECHANICS

INVISALIGN®
31 TOTAL ALIGNERS
NO REFINEMENT
7 DAY ALIGNER CHANGE

TREATMENT TIME

PROJECTED TREATMENT TIME:
15 MONTHS

ACTUAL TREATMENT TIME WITH
ACCELEDDENT:
7.5 MONTHS

“Patient compliance is key to orthodontic success. The idea of shortened treatment kept the patient motivated to wear trays ideally and cooperate with elastics.”

- Dr. Paul O’Grady

CASE STUDY



DEMOGRAPHICS

FEMALE
27 YEARS OLD

DIAGNOSIS

CLASS I
MODERATE CROWDING
NARROW ARCHES
GINGIVALLY DISPLACED
MAXILLARY CANINE
MIDLINE DISCREPANCY

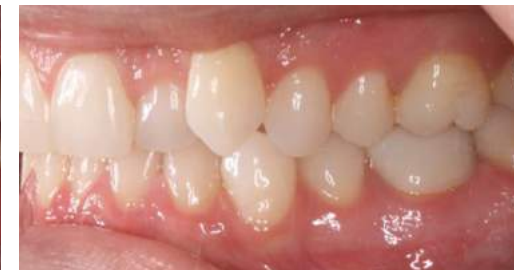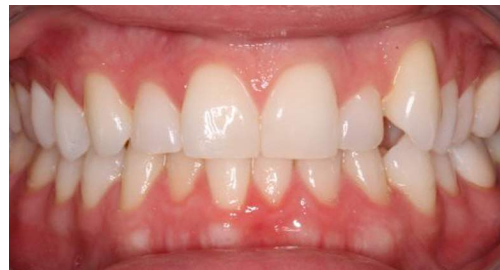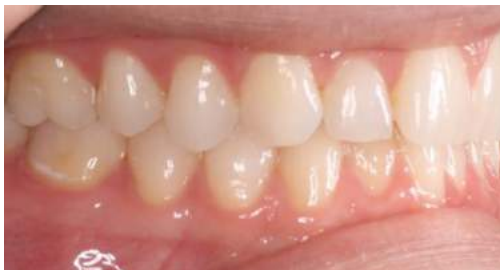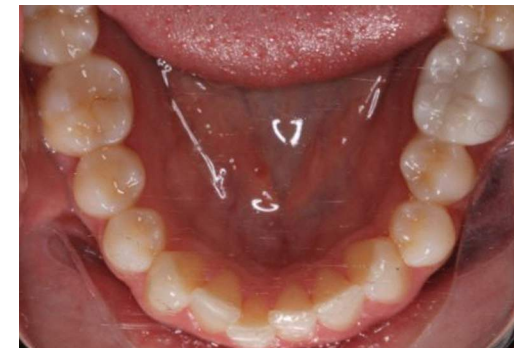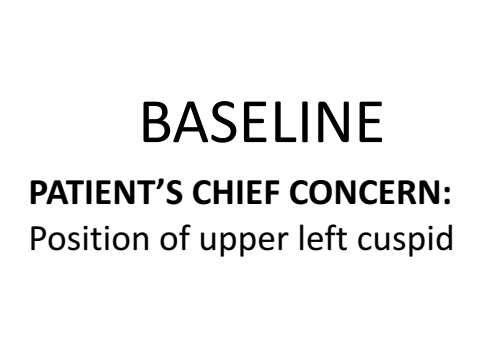
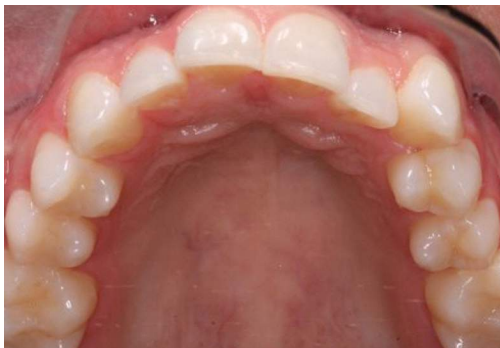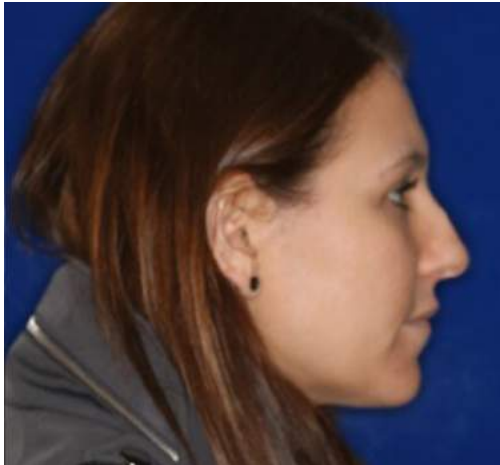MECHANICS

INVISALIGN®
31 TOTAL ALIGNERS
NO REFINEMENT
7 DAY ALIGNER CHANGE

TREATMENT TIME

PROJECTED TREATMENT
TIME:
15 MONTHS

ACTUAL TREATMENT
TIME WITH ACCELENT:
7.5 MONTHS



CASE STUDY



DEMOGRAPHICS

FEMALE
27 YEARS OLD

DIAGNOSIS

CLASS I
MODERATE CROWDING
NARROW ARCHES
GINGIVALLY DISPLACED
MAXILLARY CANINE
MIDLINE DISCREPANCY

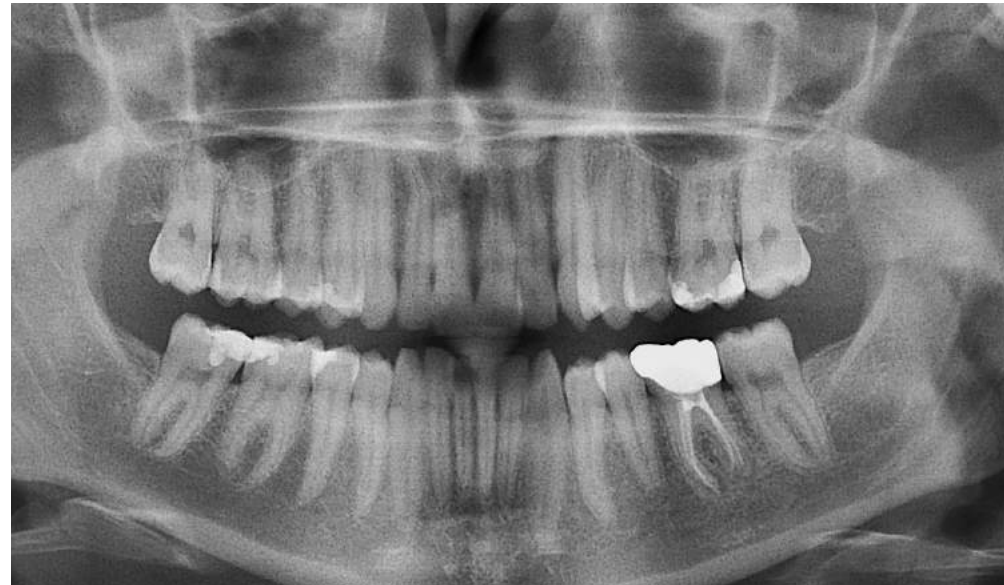
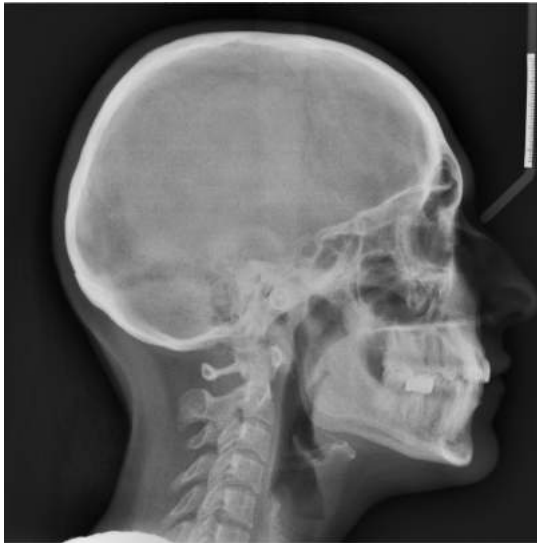MECHANICS

INVISALIGN®
31 TOTAL ALIGNERS
NO REFINEMENT
7 DAY ALIGNER CHANGE

TREATMENT TIME

PROJECTED TREATMENT
TIME:
15 MONTHS

ACTUAL TREATMENT
TIME WITH ACCELEDDENT:
7.5 MONTHS



BASELINE

CASE STUDY



DEMOGRAPHICS

FEMALE
27 YEARS OLD

DIAGNOSIS

CLASS I
MODERATE CROWDING
NARROW ARCHES
GINGIVALLY DISPLACED
MAXILLARY CANINE
MIDLINE DISCREPANCY

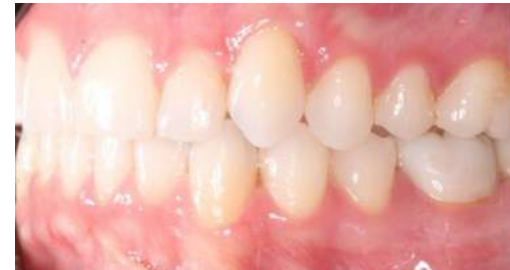
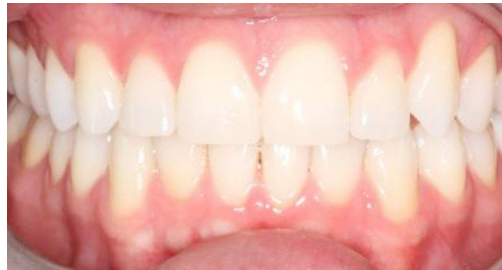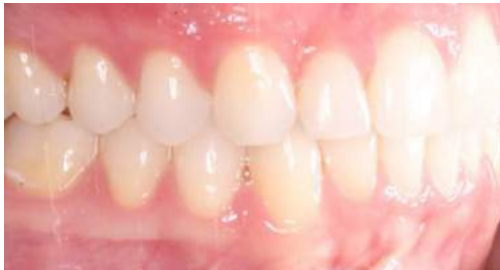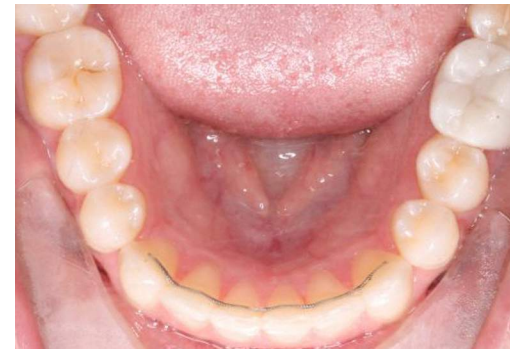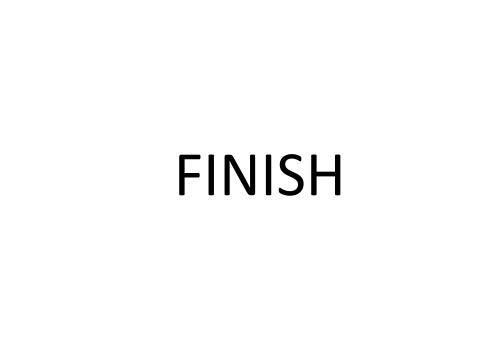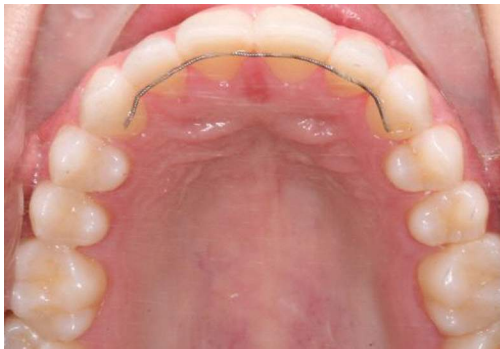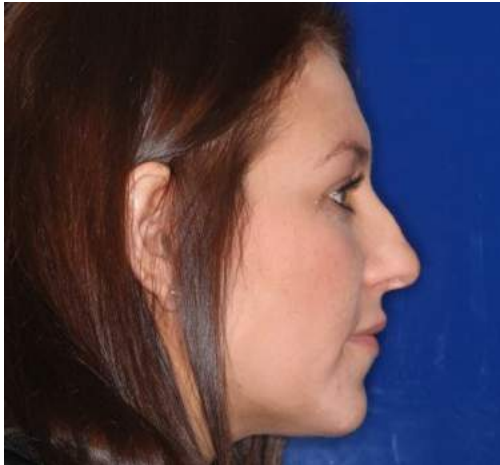MECHANICS

INVISALIGN®
31 TOTAL ALIGNERS
NO REFINEMENT
7 DAY ALIGNER CHANGE

TREATMENT TIME

PROJECTED TREATMENT
TIME:
15 MONTHS

ACTUAL TREATMENT
TIME WITH ACCELENT:
7.5 MONTHS



CASE STUDY



DEMOGRAPHICS

FEMALE
27 YEARS OLD

DIAGNOSIS

CLASS I
MODERATE CROWDING
NARROW ARCHES
GINGIVALLY DISPLACED
MAXILLARY CANINE
MIDLINE DISCREPANCY

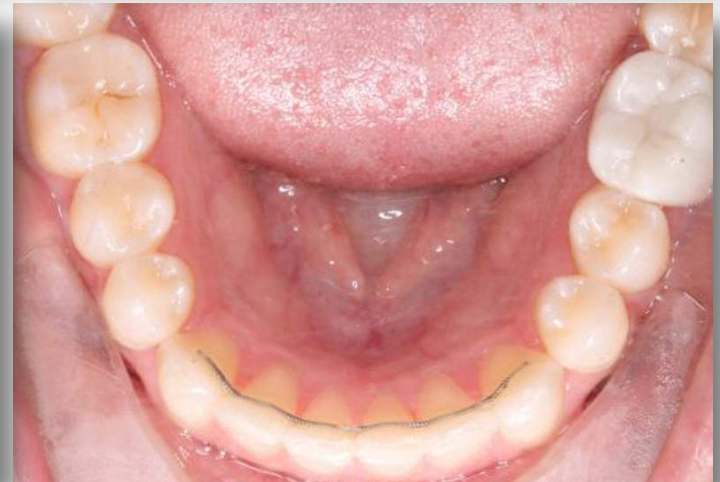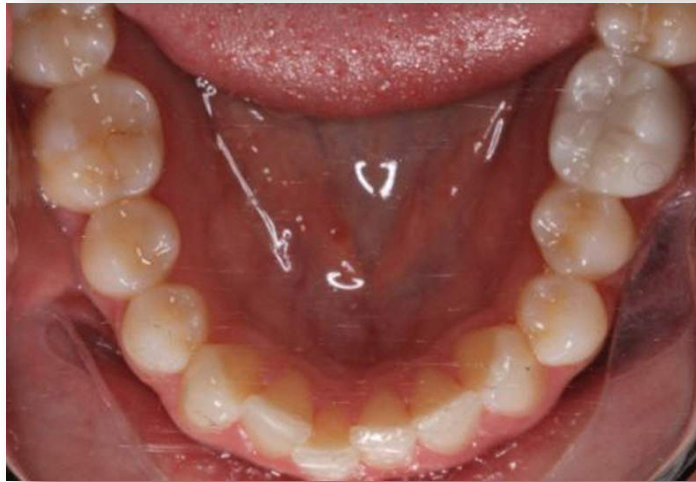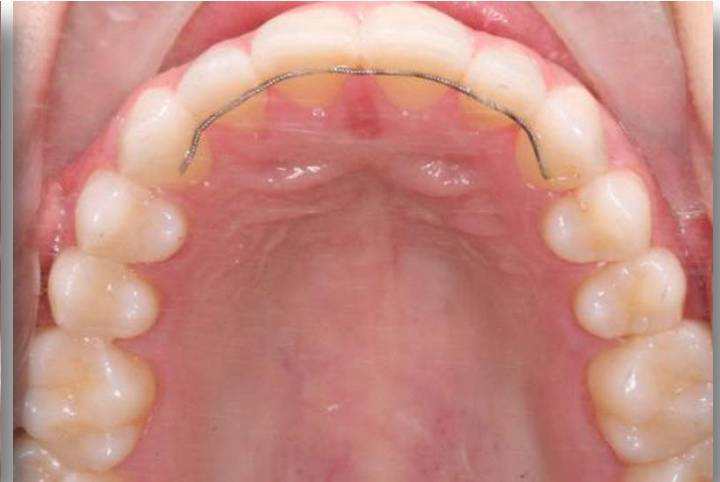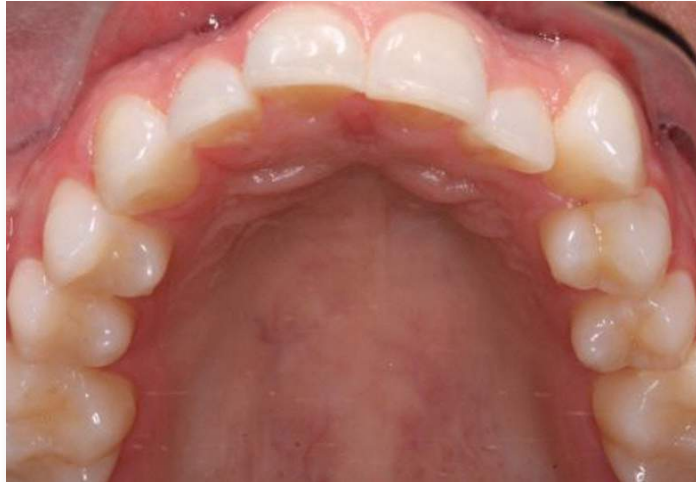MECHANICS

INVISALIGN®
31 TOTAL ALIGNERS
NO REFINEMENT
7 DAY ALIGNER CHANGE

TREATMENT TIME

PROJECTED TREATMENT
TIME:
15 MONTHS

ACTUAL TREATMENT
TIME WITH ACCELENT:
7.5 MONTHS



RESULTS: 7.5 MONTHS

CASE STUDY



DEMOGRAPHICS

FEMALE
27 YEARS OLD

DIAGNOSIS

CLASS I
MODERATE CROWDING
NARROW ARCHES
GINGIVALLY DISPLACED
MAXILLARY CANINE
MIDLINE DISCREPANCY

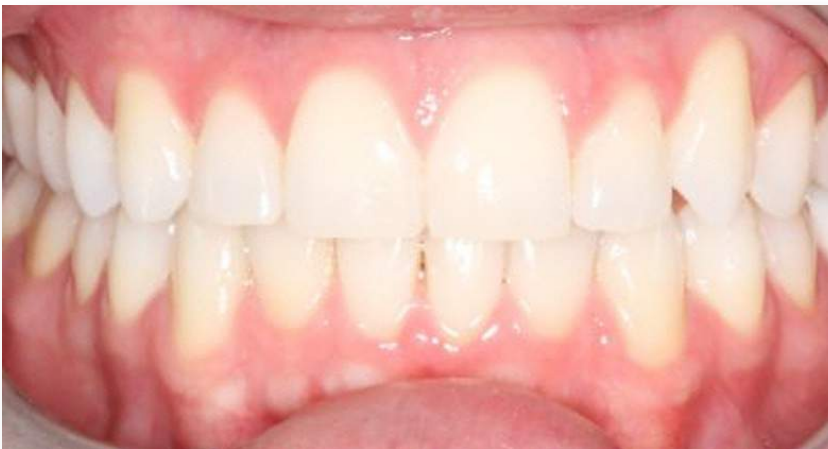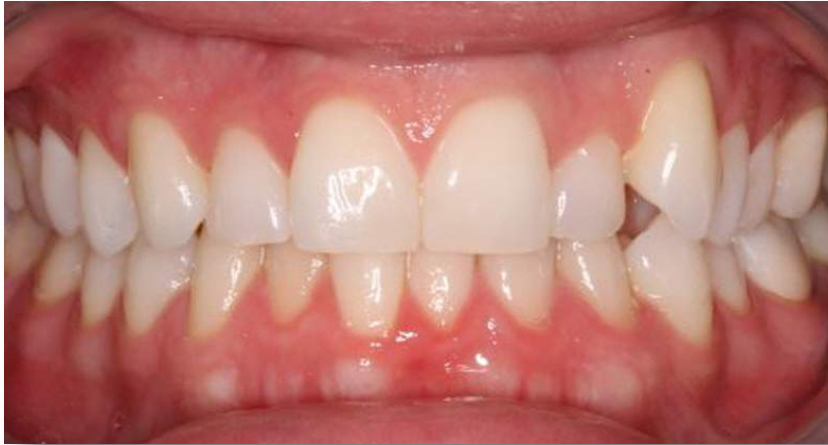MECHANICS

INVISALIGN®
31 TOTAL ALIGNERS
NO REFINEMENT
7 DAY ALIGNER CHANGE

TREATMENT TIME

PROJECTED TREATMENT
TIME:
15 MONTHS

ACTUAL TREATMENT
TIME WITH ACCELENT:
7.5 MONTHS



RESULTS: 7.5 MONTHS