

CASE STUDY



DEMOGRAPHICS

MALE
20 YEARS OLD

DIAGNOSIS

CLASS III
CROWDING
NARROW ARCHES
ANTERIOR CROSSBITE
POSTERIOR CROSSBITE
MANDIBULAR
PROGNATHISM

MECHANICS

IN-OVATION® SELF-
LIGATING BRACKETS
SURGERY

TREATMENT TIME

PROJECTED TREATMENT TIME:
18 MONTHS

ACTUAL TREATMENT TIME WITH
ACCELEDENT:
12 MONTHS

“The patient was very motivated and looked forward to seeing his progress with accelerated orthodontic movements in preparation for orthognathic surgery.”

- Dr. Kevin McGrath

CASE STUDY



DEMOGRAPHICS

MALE
20 YEARS OLD

DIAGNOSIS

CLASS III
CROWDING
NARROW ARCHES
ANTERIOR CROSSBITE
POSTERIOR CROSSBITE
MANDIBULAR
PROGNATHISM

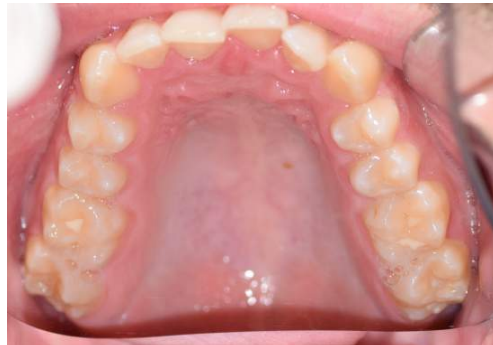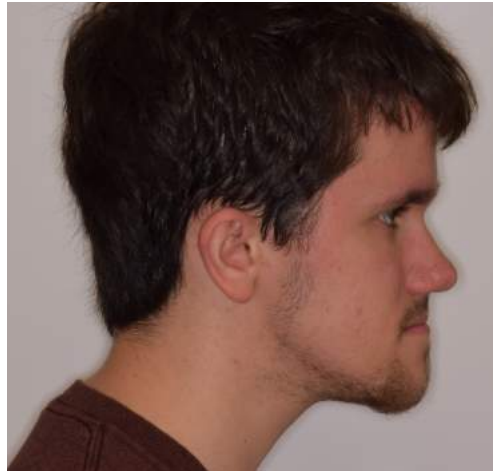
MECHANICS

IN-OVATION® SELF-
LIGATING BRACKETS
SURGERY

TREATMENT TIME

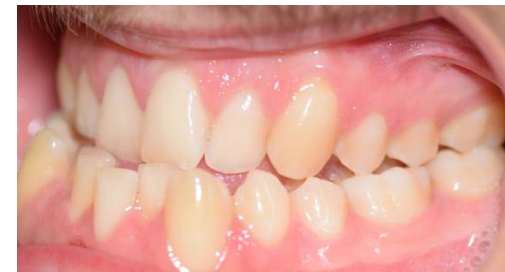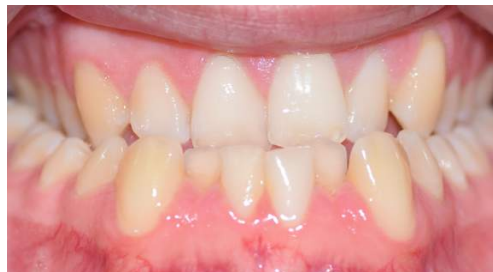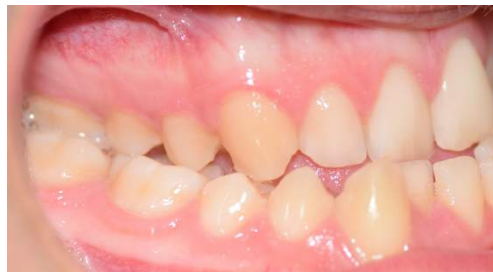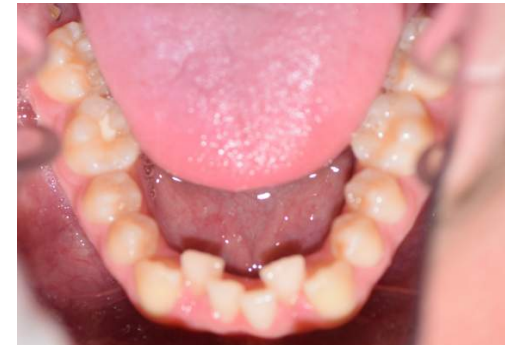PROJECTED TREATMENT
TIME:
18 MONTHS

ACTUAL TREATMENT
TIME WITH ACCELENT:
12 MONTHS



BASELINE

Patient Chief Concern:
Crowded teeth & jaw
discrepancy



CASE STUDY



DEMOGRAPHICS

MALE
20 YEARS OLD

DIAGNOSIS

CLASS III
CROWDING
NARROW ARCHES
ANTERIOR CROSSBITE
POSTERIOR CROSSBITE
MANDIBULAR
PROGNATHISM

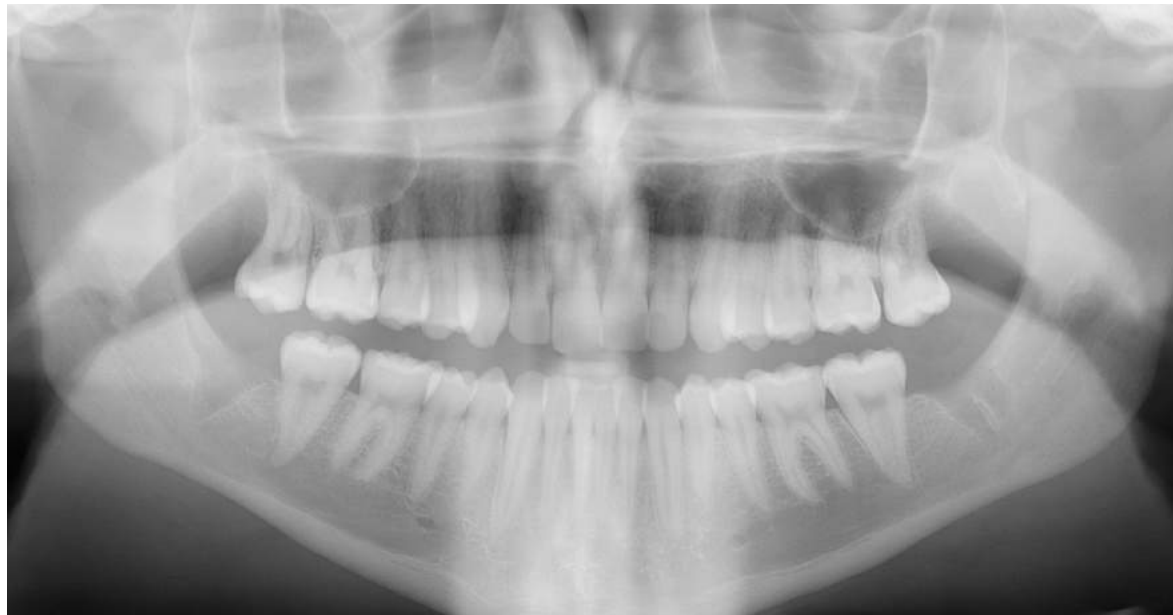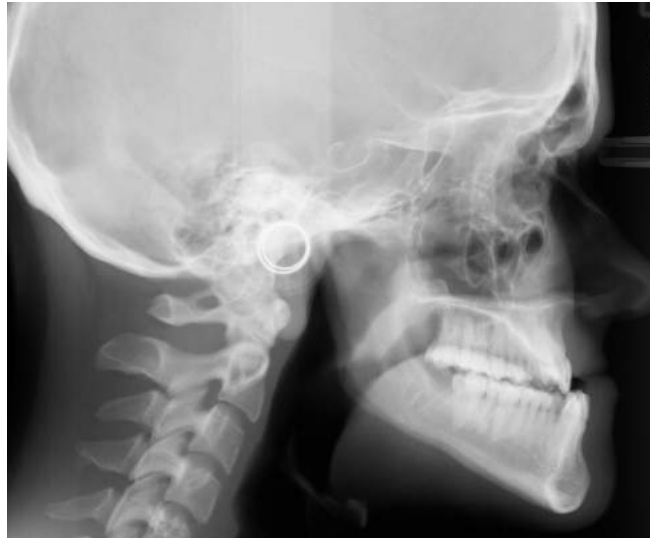MECHANICS

IN-OVATION® SELF-
LIGATING BRACKETS
SURGERY

TREATMENT TIME

PROJECTED TREATMENT
TIME:
18 MONTHS

ACTUAL TREATMENT
TIME WITH ACCELEDENT:
12 MONTHS



CASE STUDY



DEMOGRAPHICS

MALE
20 YEARS OLD

DIAGNOSIS

CLASS III
CROWDING
NARROW ARCHES
ANTERIOR CROSSBITE
POSTERIOR CROSSBITE
MANDIBULAR
PROGNATHISM

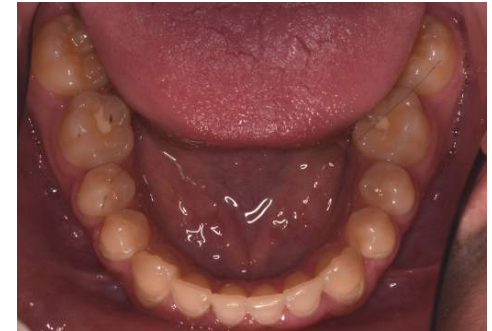
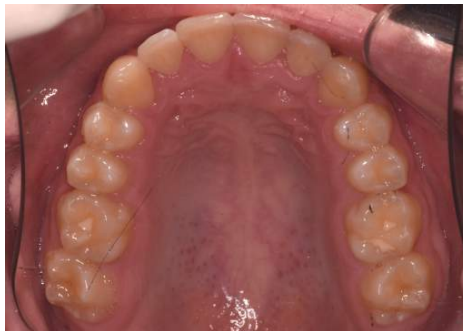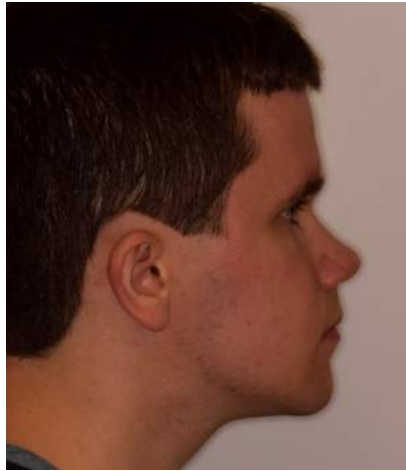MECHANICS

IN-OVATION® SELF-
LIGATING BRACKETS
SURGERY

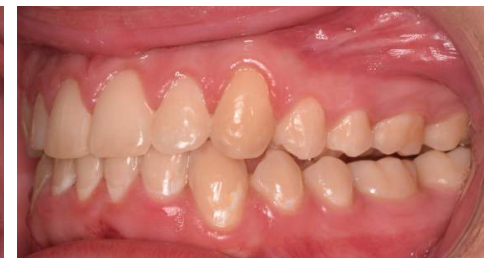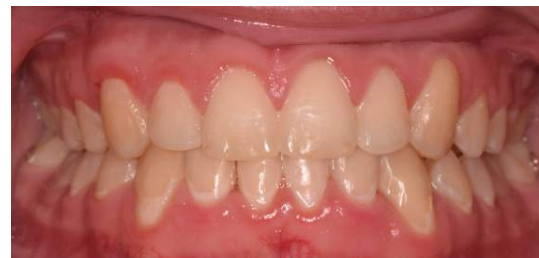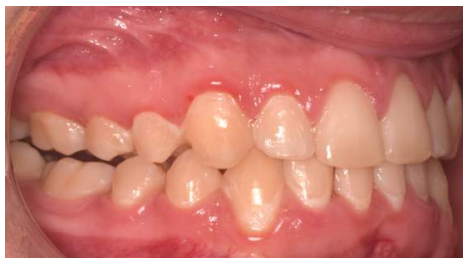TREATMENT TIME

PROJECTED TREATMENT
TIME:
18 MONTHS

ACTUAL TREATMENT
TIME WITH ACCELENT:
12 MONTHS



FINISH



CASE STUDY



DEMOGRAPHICS

MALE
20 YEARS OLD

DIAGNOSIS

CLASS III
CROWDING
NARROW ARCHES
ANTERIOR CROSSBITE
POSTERIOR CROSSBITE
MANDIBULAR
PROGNATHISM

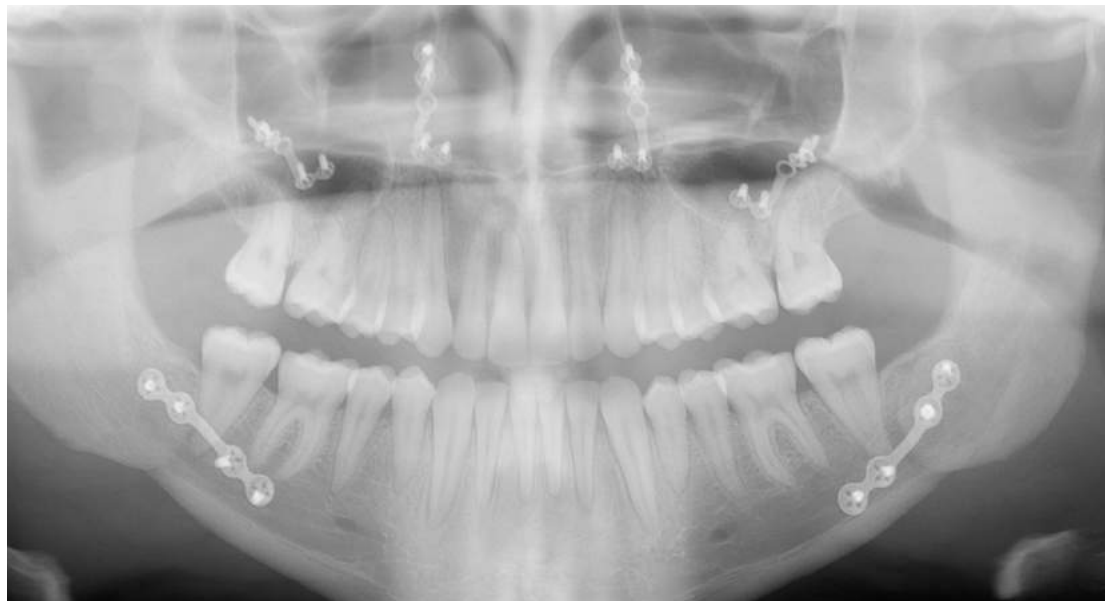
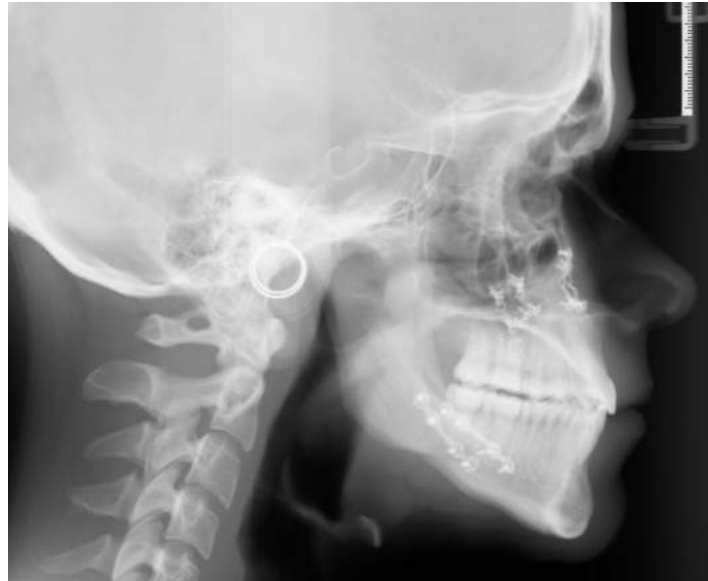MECHANICS

IN-OVATION® SELF-
LIGATING BRACKETS
SURGERY

TREATMENT TIME

PROJECTED TREATMENT
TIME:
18 MONTHS

ACTUAL TREATMENT
TIME WITH ACCELEDENT:
12 MONTHS



DEMOGRAPHICS

MALE
20 YEARS OLD

DIAGNOSIS

CLASS III
CROWDING
NARROW ARCHES
ANTERIOR CROSSBITE
POSTERIOR CROSSBITE
MANDIBULAR
PROGNATHISM

MECHANICS

IN-OVATION® SELF-
LIGATING BRACKETS
SURGERY

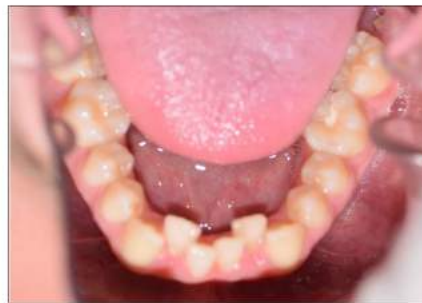TREATMENT TIME

PROJECTED TREATMENT
TIME:
18 MONTHS

ACTUAL TREATMENT
TIME WITH ACCELEDENT:
12 MONTHS

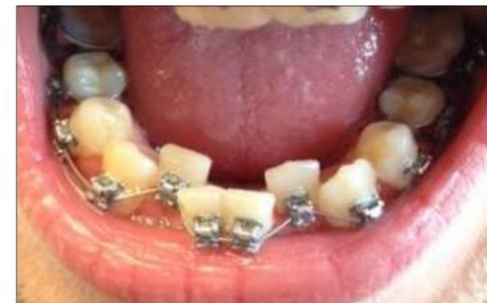ACCELEDENT REALLY WORKS!

This is an actual patient here at Oakton Family Orthodontics

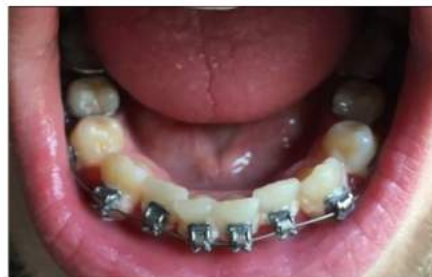

8/5/2015

AcceleDent works gently to soften the bone with gradual initial results. **Pictured left** was taken by our office as a part of the initial composite photos. **Pictured right** is the first photo taken by the patient to document his results. As shown, you will begin to see movement after about 3 months.

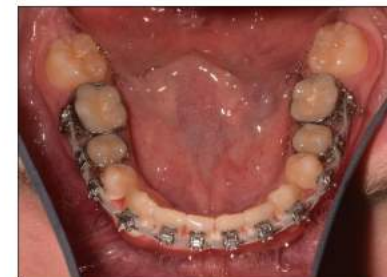

11/25/2015



12/18/2015

Pictured left is a photo taken by the patient one month later showing the a significant change due to dedicated, continued use of the device. **Pictured right** is a progress photo taken by our office as the accelerated movement continues.



04/11/2016

The patient was excited to share his progress in this communication piece the practice created to share with other patients.

CASE STUDY



DEMOGRAPHICS

MALE
20 YEARS OLD

DIAGNOSIS

CLASS III
CROWDING
NARROW ARCHES
ANTERIOR CROSSBITE
POSTERIOR CROSSBITE
MANDIBULAR
PROGNATHISM

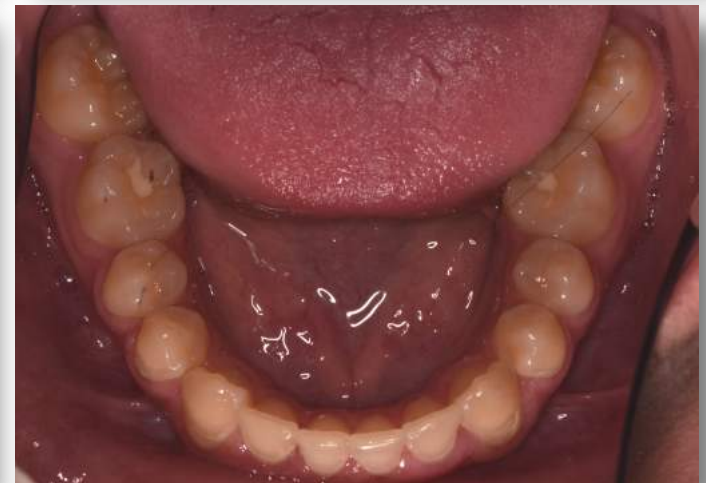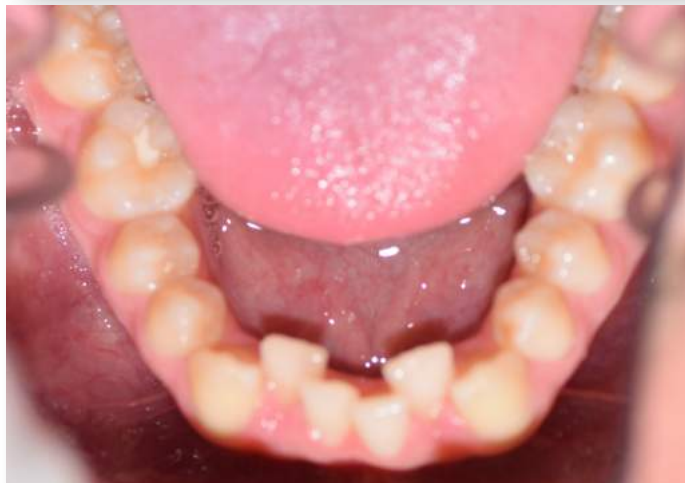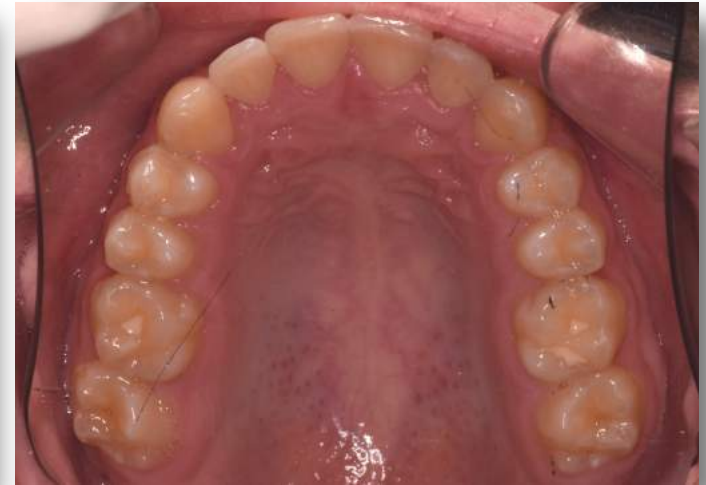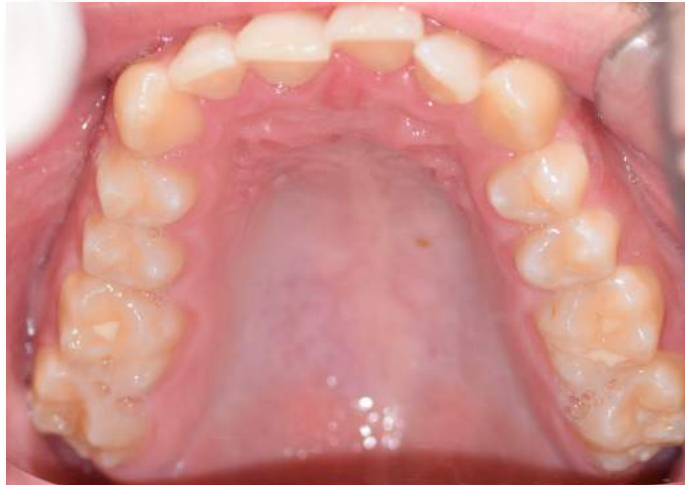MECHANICS

IN-OVATION® SELF-
LIGATING BRACKETS
SURGERY

TREATMENT TIME

PROJECTED TREATMENT
TIME:
18 MONTHS

ACTUAL TREATMENT
TIME WITH ACCELENT:
12 MONTHS



RESULTS: 12 MONTHS

CASE STUDY



DEMOGRAPHICS

MALE
20 YEARS OLD

DIAGNOSIS

CLASS III
CROWDING
NARROW ARCHES
ANTERIOR CROSSBITE
POSTERIOR CROSSBITE
MANDIBULAR
PROGNATHISM

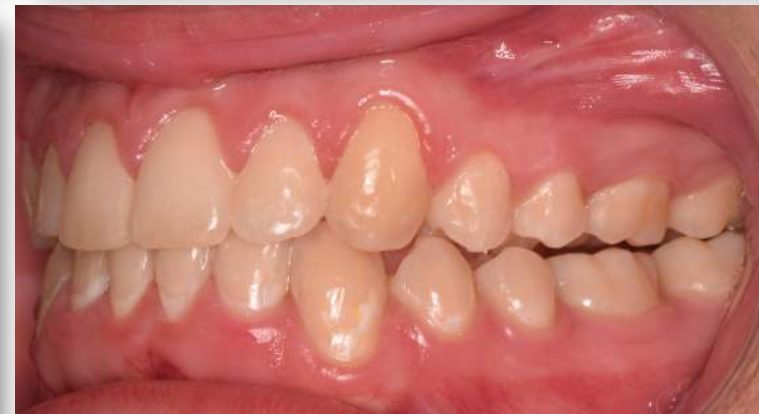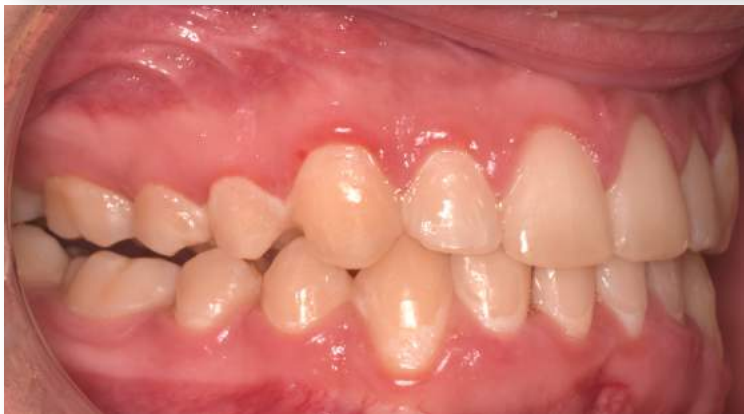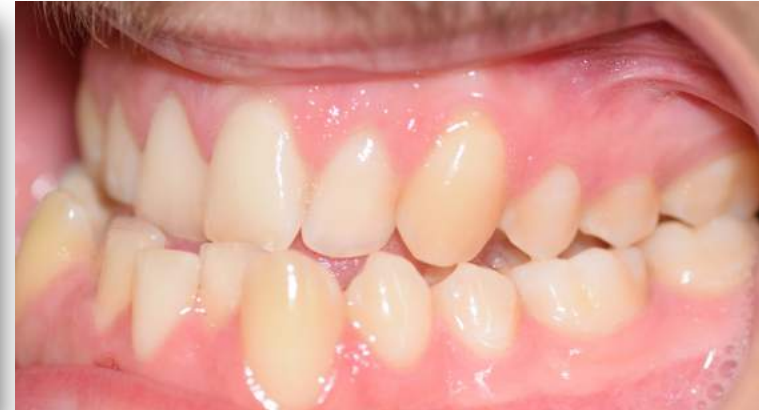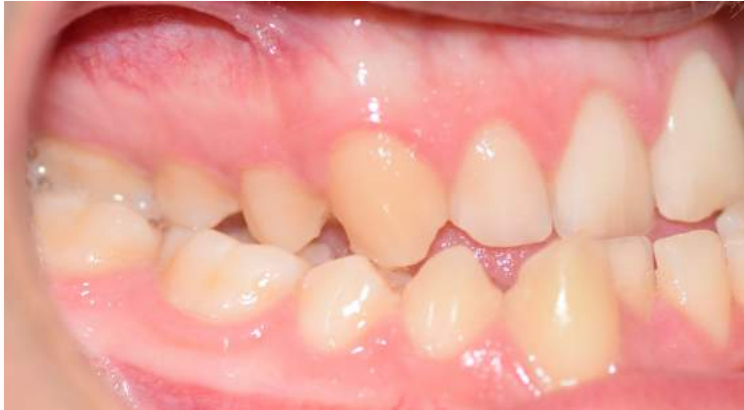MECHANICS

IN-OVATION® SELF-
LIGATING BRACKETS
SURGERY

TREATMENT TIME

PROJECTED TREATMENT
TIME:
18 MONTHS

ACTUAL TREATMENT
TIME WITH ACCELENT:
12 MONTHS



RESULTS: 12 MONTHS

CASE STUDY



DEMOGRAPHICS

MALE
20 YEARS OLD

DIAGNOSIS

CLASS III
CROWDING
NARROW ARCHES
ANTERIOR CROSSBITE
POSTERIOR CROSSBITE
MANDIBULAR
PROGNATHISM

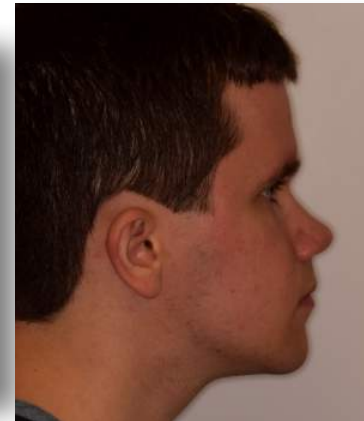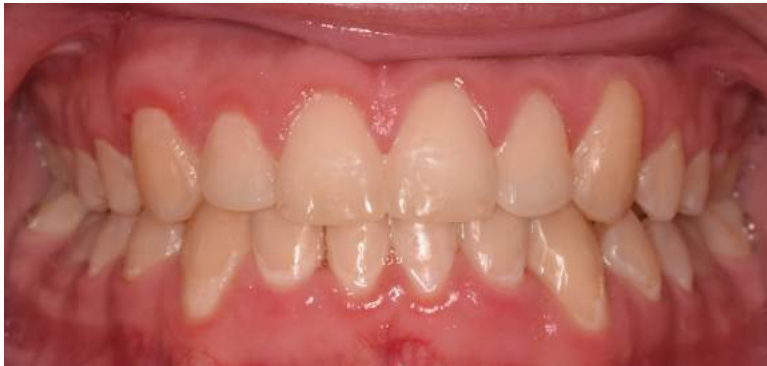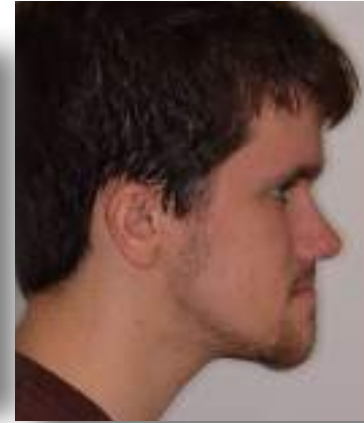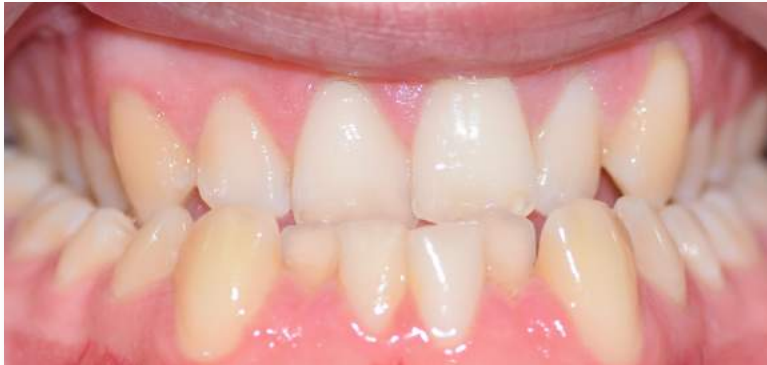MECHANICS

IN-OVATION® SELF-
LIGATING BRACKETS
SURGERY

TREATMENT TIME

PROJECTED TREATMENT
TIME:
18 MONTHS

ACTUAL TREATMENT
TIME WITH ACCELENT:
12 MONTHS



RESULTS: 12 MONTHS

CASE STUDY



DEMOGRAPHICS

MALE
20 YEARS OLD

DIAGNOSIS

CLASS III
CROWDING
NARROW ARCHES
ANTERIOR CROSSBITE
POSTERIOR CROSSBITE
MANDIBULAR
PROGNATHISM

MECHANICS

IN-OVATION® SELF-
LIGATING BRACKETS
SURGERY

TREATMENT TIME

PROJECTED TREATMENT
TIME:
18 MONTHS

ACTUAL TREATMENT
TIME WITH ACCELENT:
12 MONTHS

